

## Chest X-ray Path correlation

- Normal structures
- Densities
- Genesis of abnormal densities
- Localization
- Pathological correlation
- Steps in evaluation of CXR

---

---

---

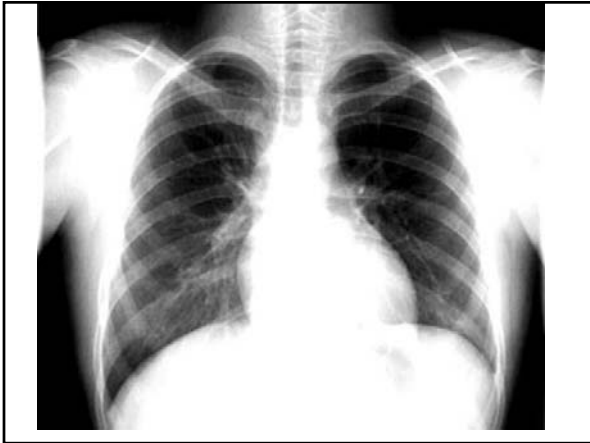---

---

---

---

---



---

---

---

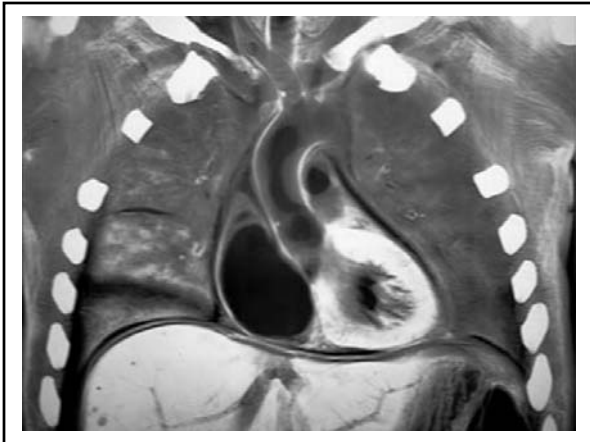
---

---

---

---

---



---

---

---

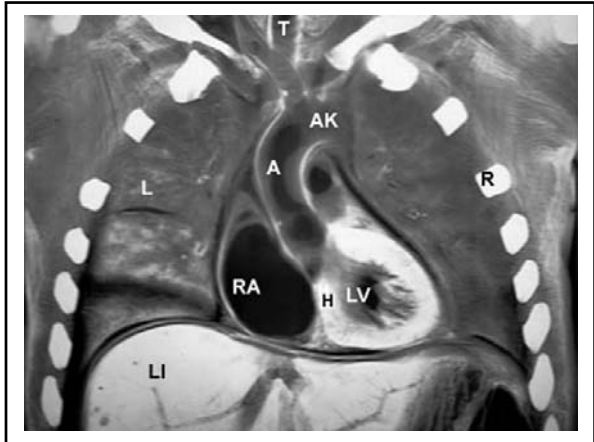
---

---

---

---

---



---

---

---

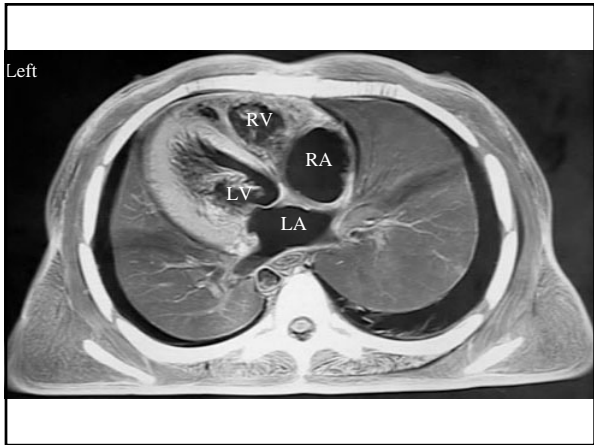
---

---

---

---

---



---

---

---

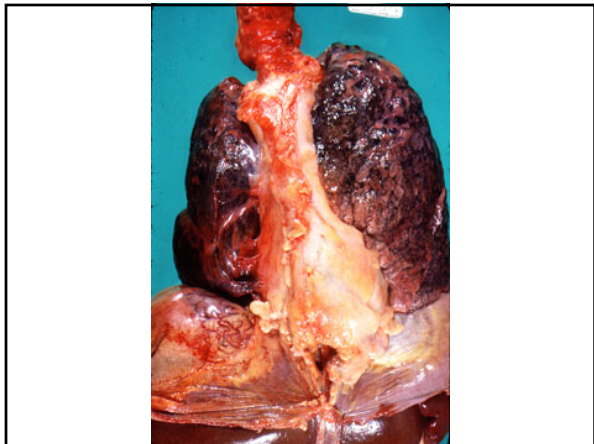
---

---

---

---

---



---

---

---

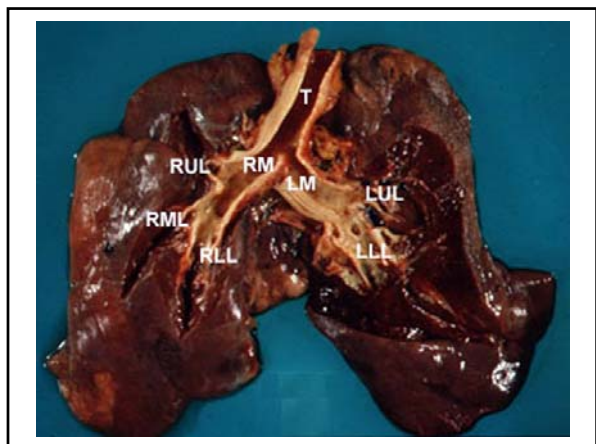
---

---

---

---

---



---

---

---

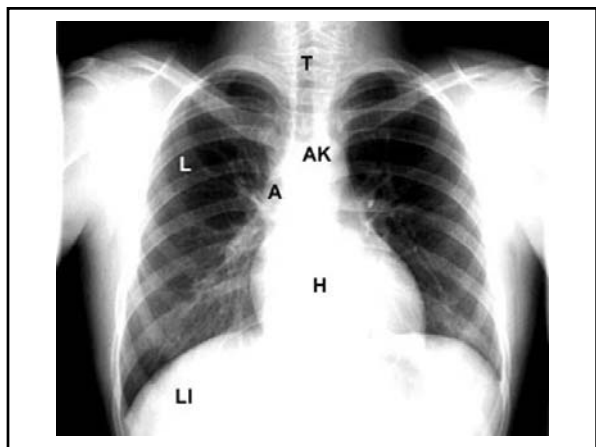
---

---

---

---

---



---

---

---

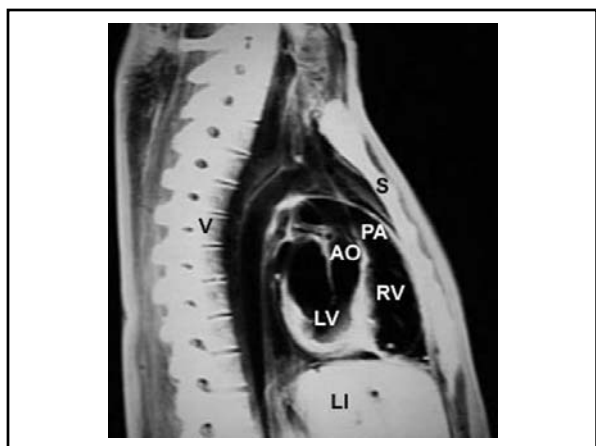
---

---

---

---

---



---

---

---

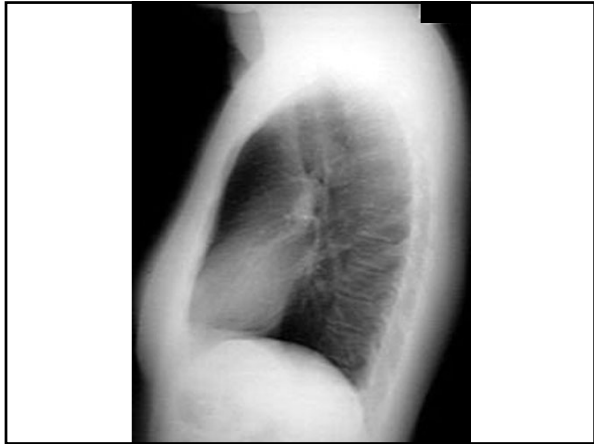---

---

---

---

---



---

---

---

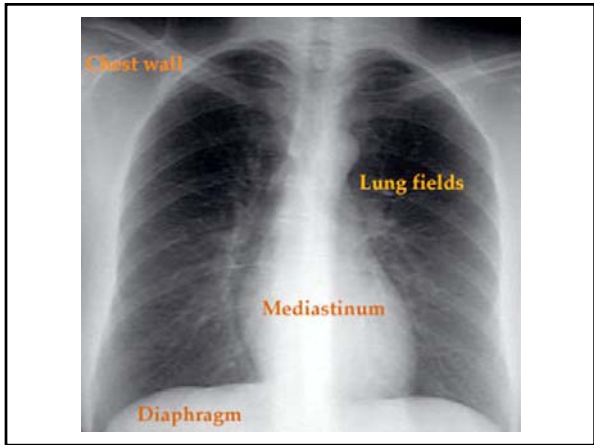
---

---

---

---

---



---

---

---

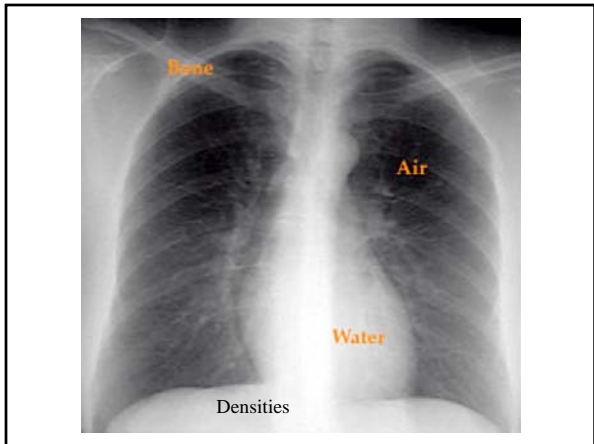
---

---

---

---

---



---

---

---

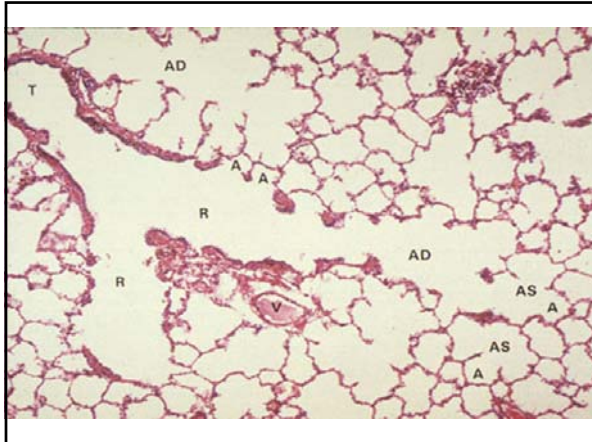
---

---

---

---

---



---

---

---

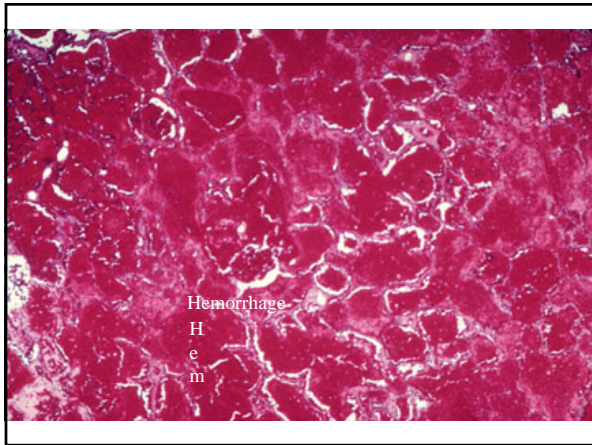
---

---

---

---

---



---

---

---

---

---

---

---

---

**Localization**

- Lobar distribution
- Air bronchogram
- Silhouette sign
- Extra pleural sign

---

---

---

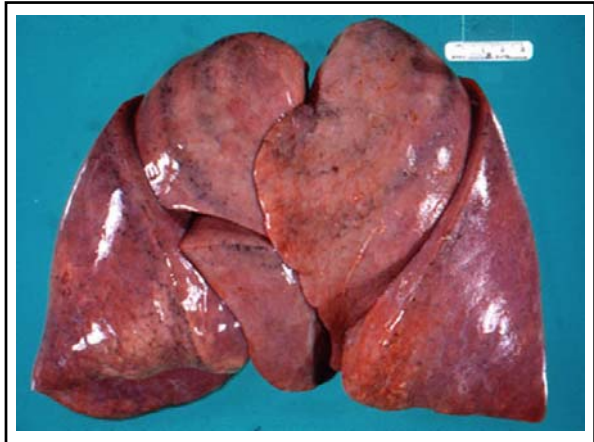---

---

---

---

---



---

---

---

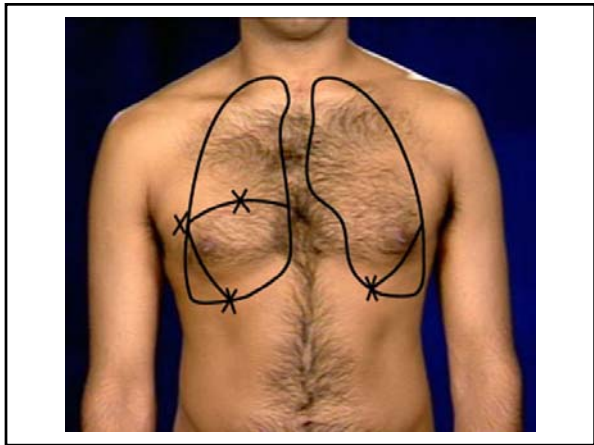
---

---

---

---

---



---

---

---

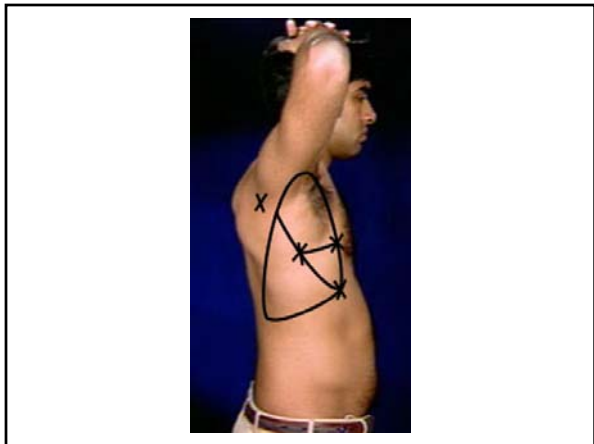---

---

---

---

---



---

---

---

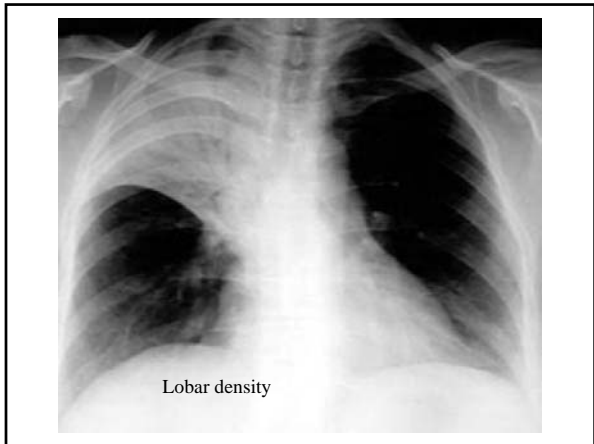
---

---

---

---

---



---

---

---

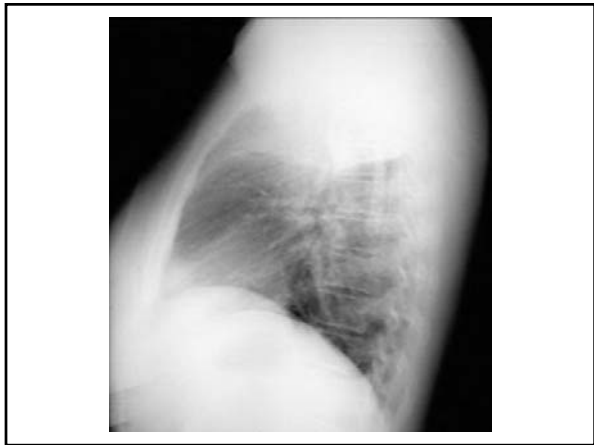
---

---

---

---

---



---

---

---

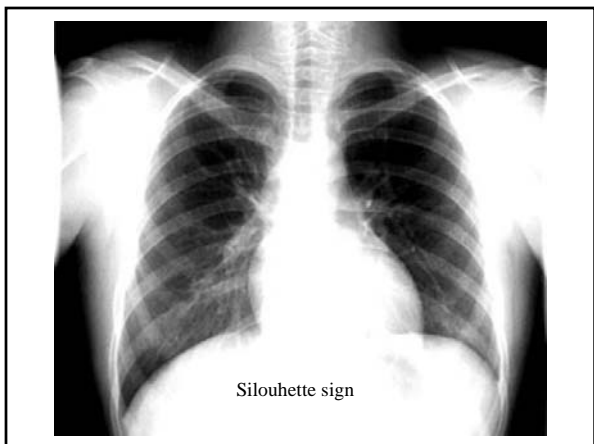---

---

---

---

---



---

---

---

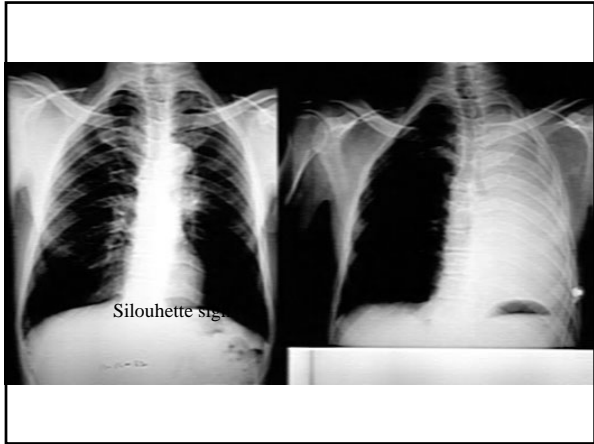---

---

---

---

---



---

---

---

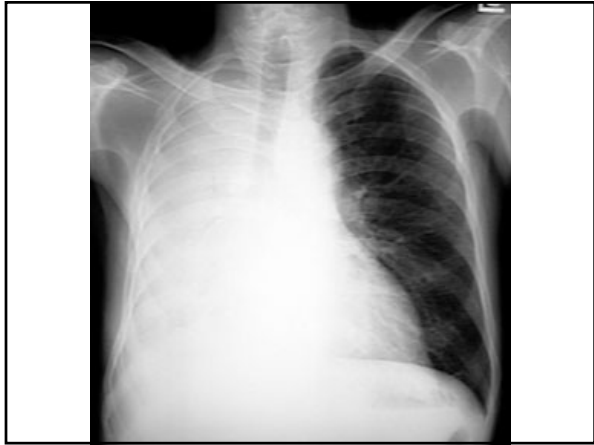---

---

---

---

---



---

---

---

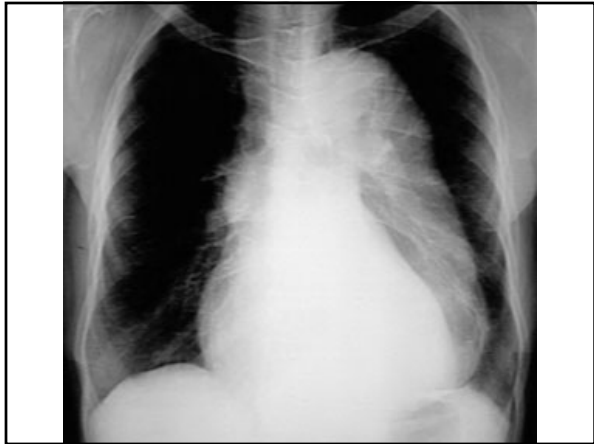---

---

---

---

---



---

---

---

---

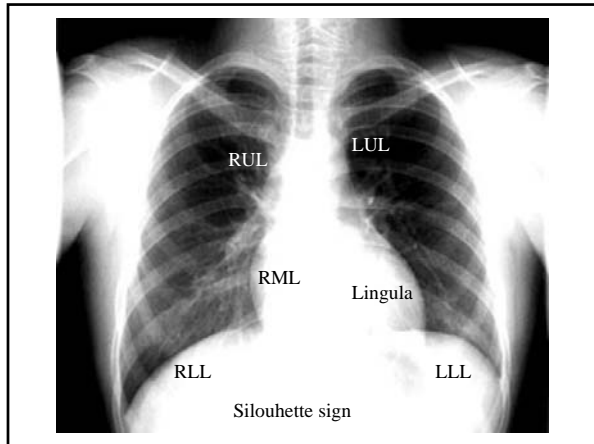
---

---

---

---





---

---

---

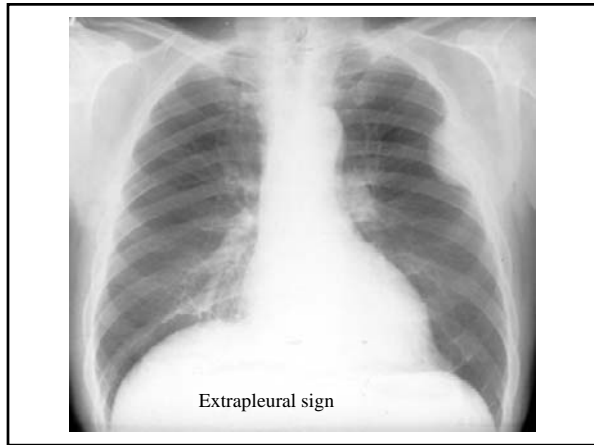
---

---

---

---

---



---

---

---

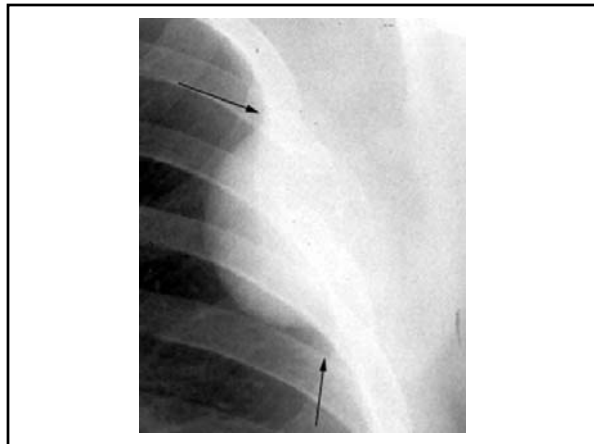
---

---

---

---

---



---

---

---

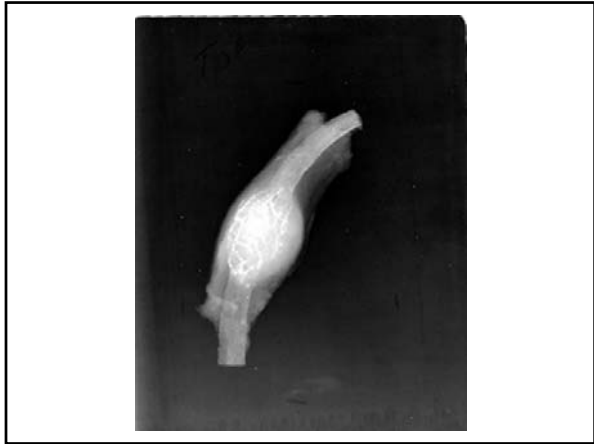---

---

---

---

---



---

---

---

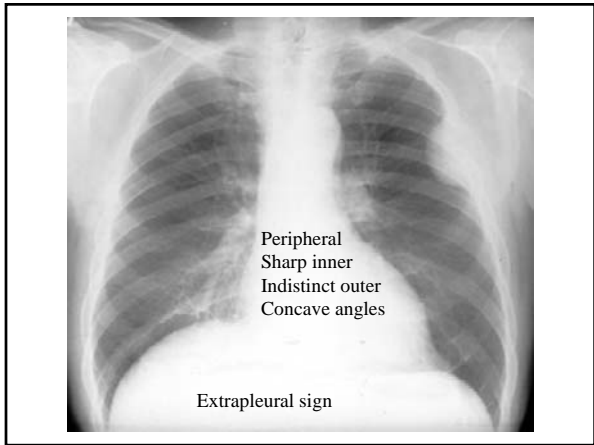
---

---

---

---

---



---

---

---

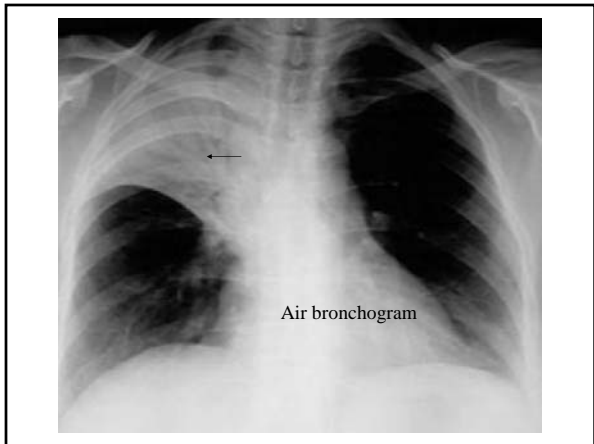
---

---

---

---

---



---

---

---

---

---

---

---

---

## Pathological correlation

- Consolidation
- Cavitation
- Mass
- Atelectasis
- Pleural effusion
- Pneumothorax
- Pulmonary edema

---

---

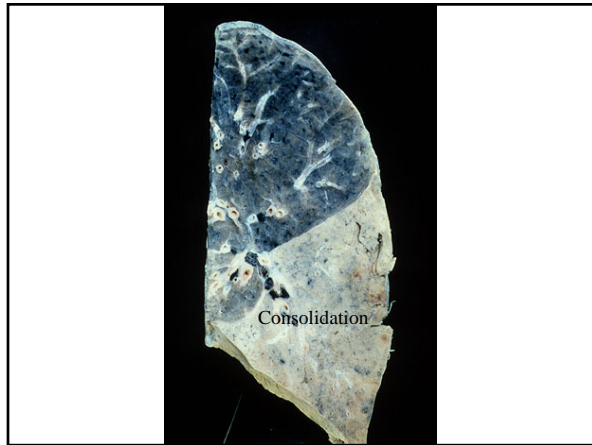---

---

---

---

---



---

---

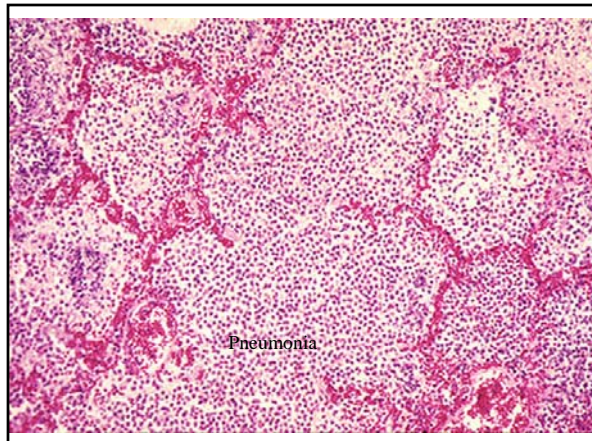
---

---

---

---

---



---

---

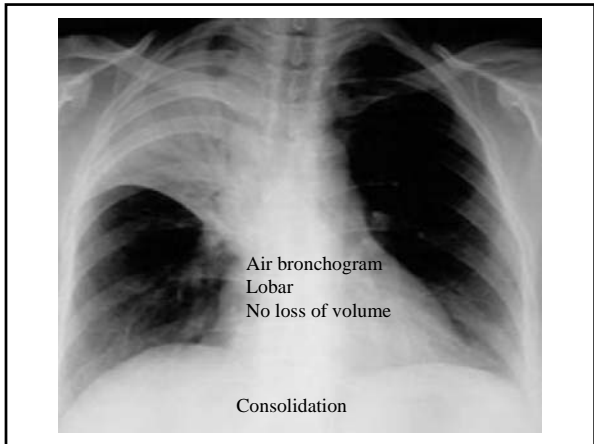
---

---

---

---

---



---

---

---

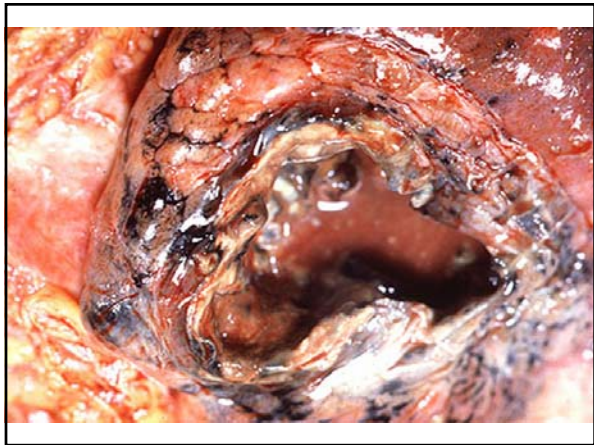
---

---

---

---

---



---

---

---

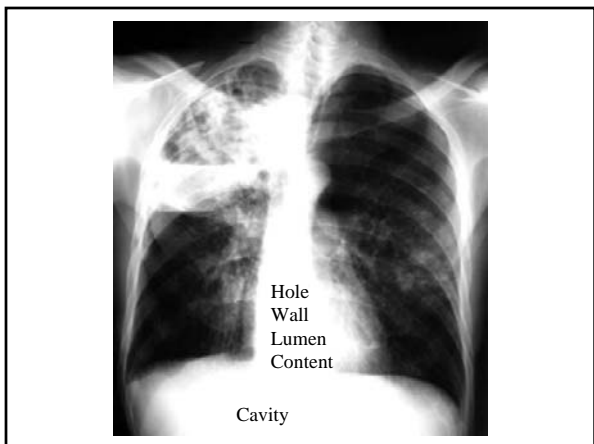
---

---

---

---

---



---

---

---

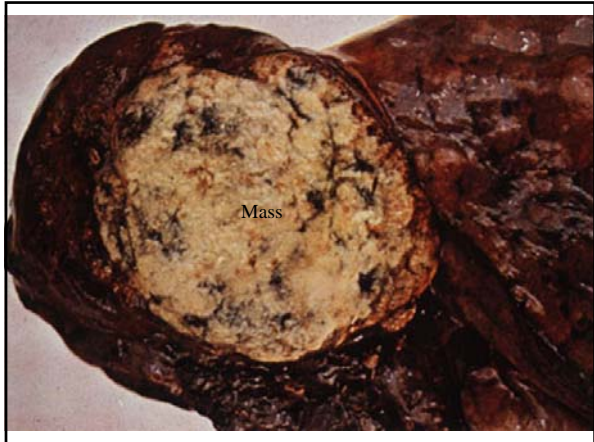---

---

---

---

---



---

---

---

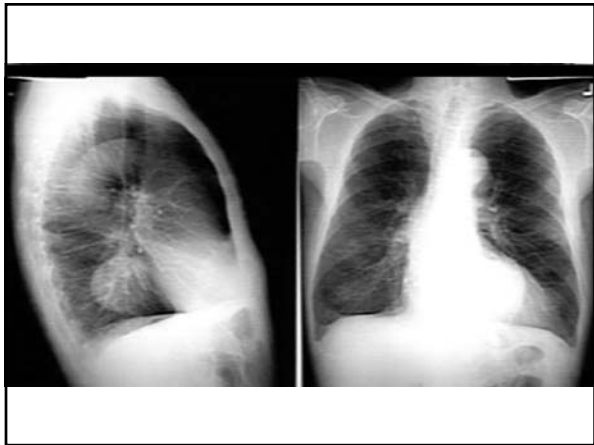---

---

---

---

---



---

---

---

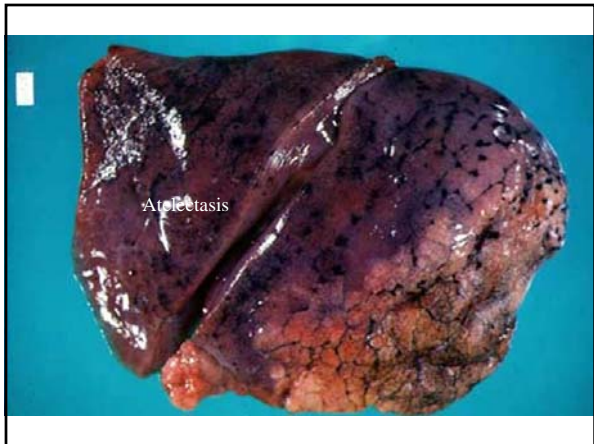
---

---

---

---

---



---

---

---

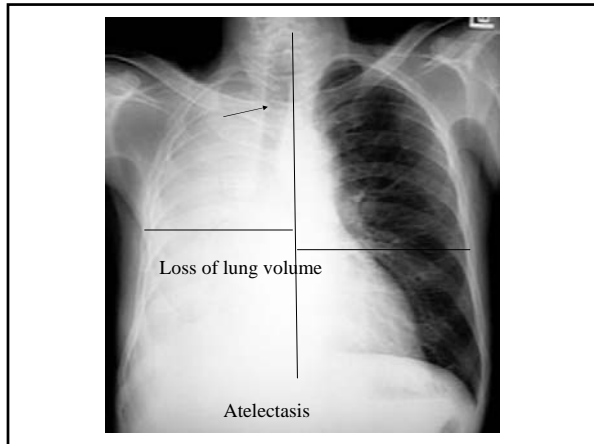
---

---

---

---

---



---

---

---

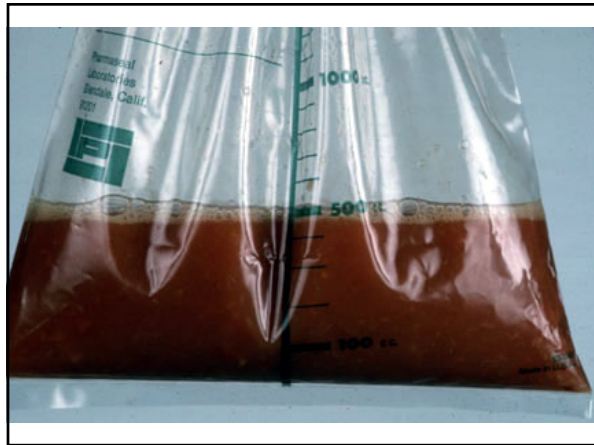---

---

---

---

---



---

---

---

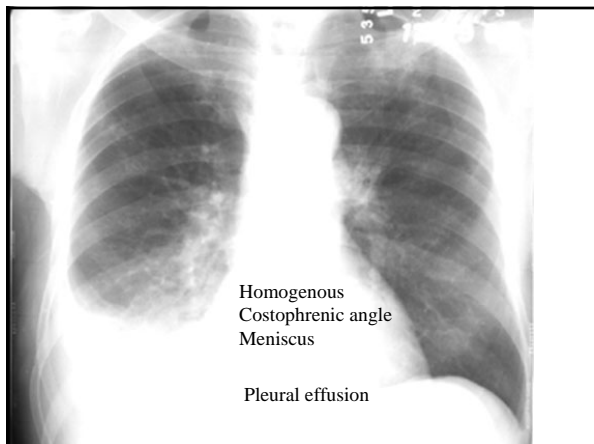
---

---

---

---

---



---

---

---

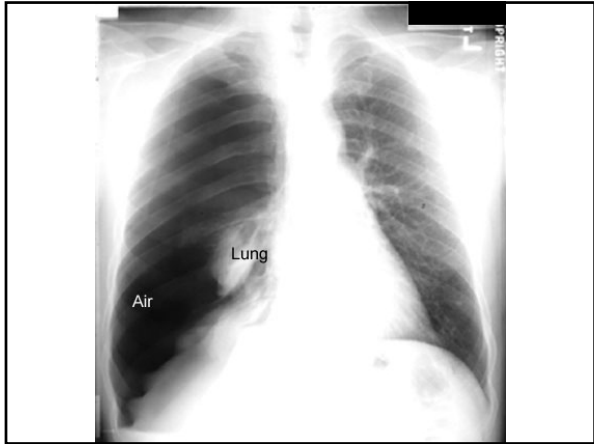
---

---

---

---

---



---

---

---

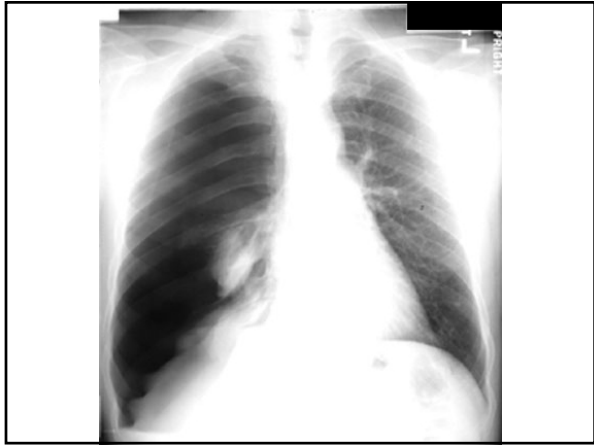---

---

---

---

---



---

---

---

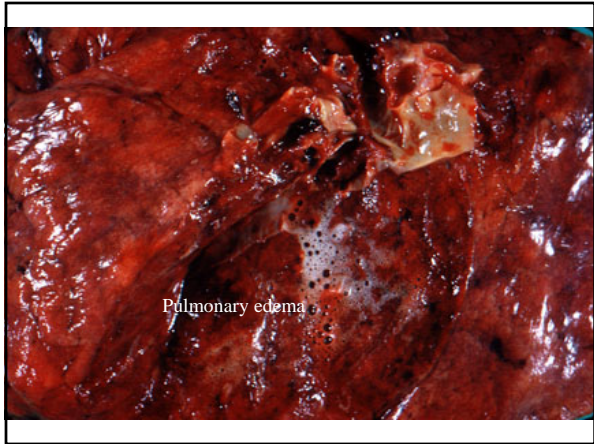---

---

---

---

---



---

---

---

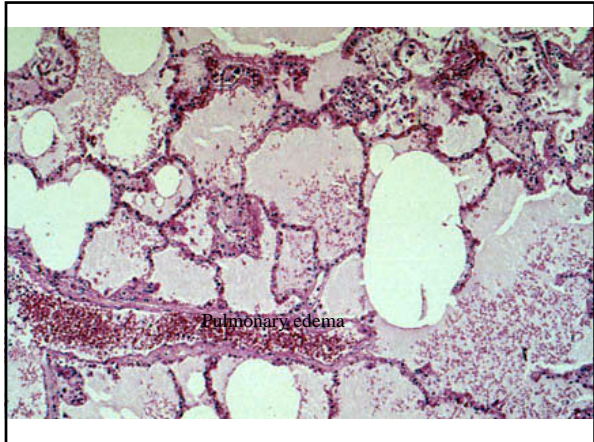
---

---

---

---

---



---

---

---

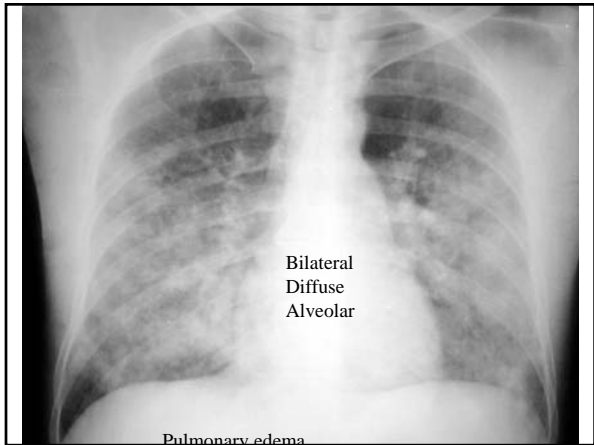
---

---

---

---

---



---

---

---

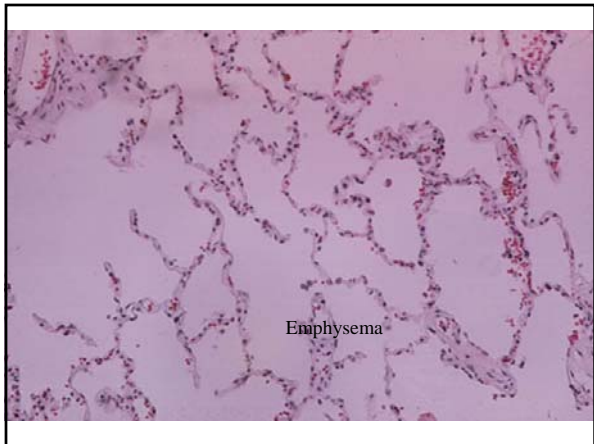
---

---

---

---

---



---

---

---

---

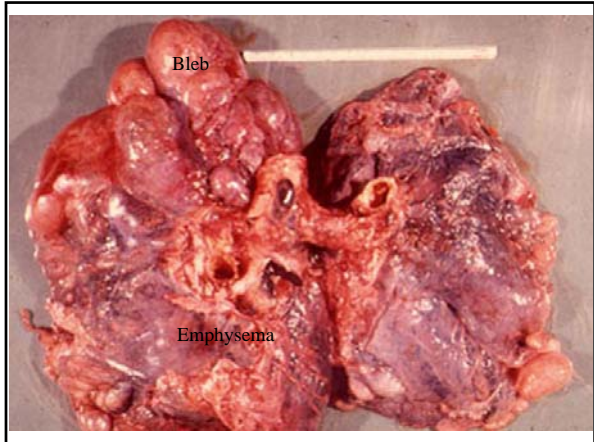
---

---

---

---





---

---

---

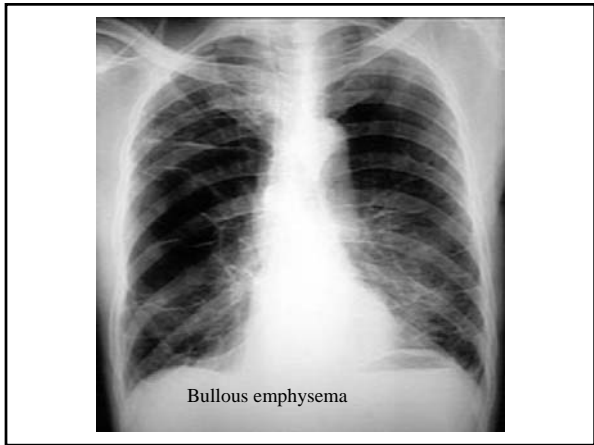
---

---

---

---

---



---

---

---

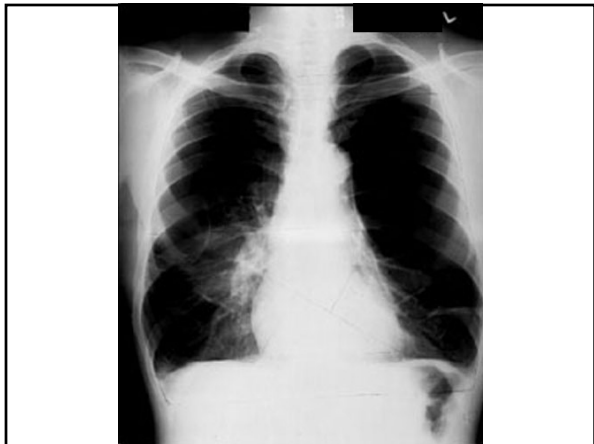---

---

---

---

---



---

---

---

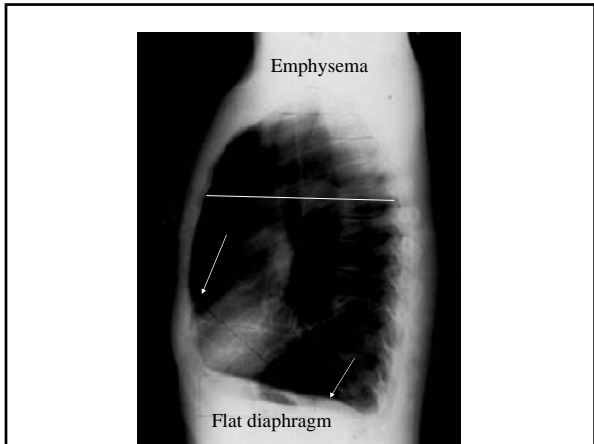
---

---

---

---

---



---

---

---

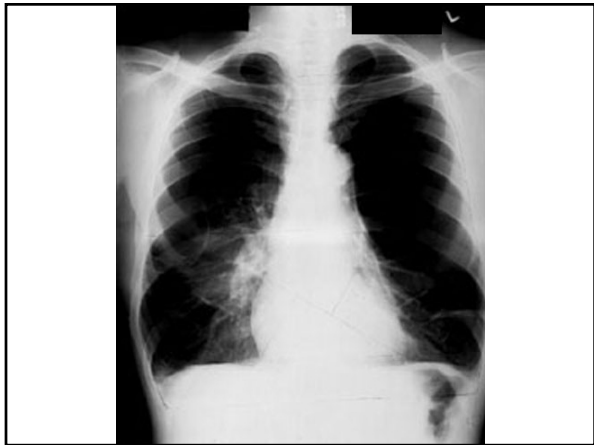---

---

---

---

---



---

---

---

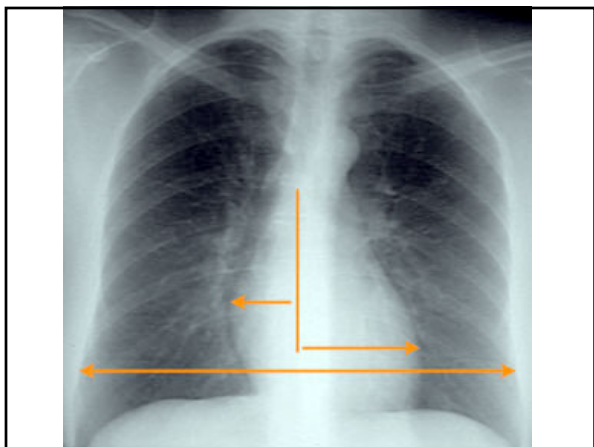
---

---

---

---

---



---

---

---

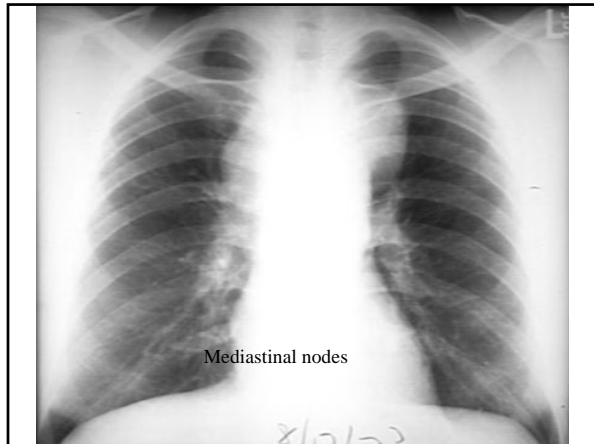---

---

---

---

---



---

---

---

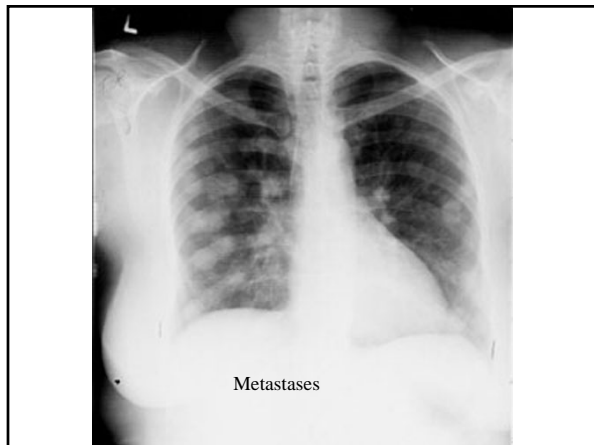
---

---

---

---

---



---

---

---

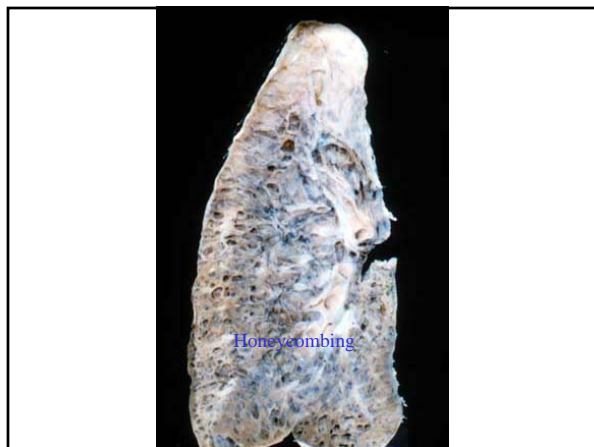
---

---

---

---

---



---

---

---

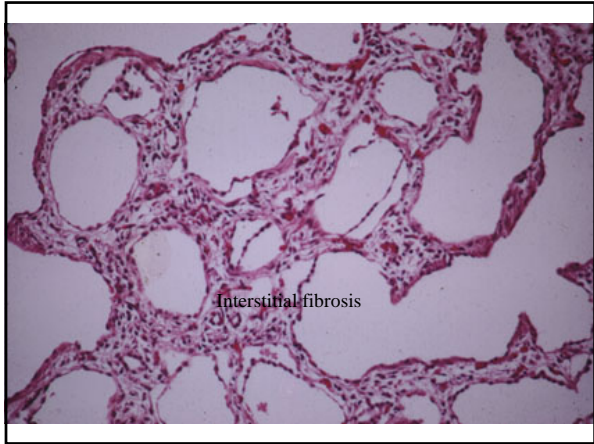
---

---

---

---

---



---

---

---

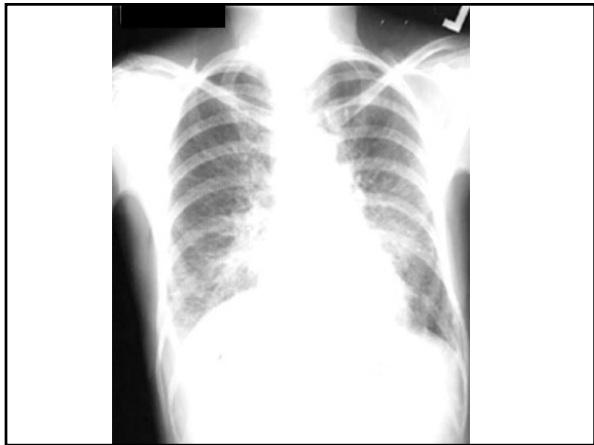---

---

---

---

---



---

---

---

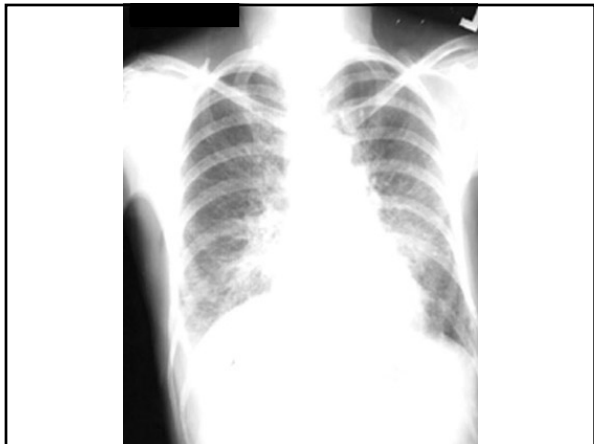---

---

---

---

---



---

---

---

---

---

---

---

---

## Steps in evaluation of CXR

- Identify abnormalities
- Localize
- Identify pathological process
- Probable etiology
- Tests to confirm

---

---

---

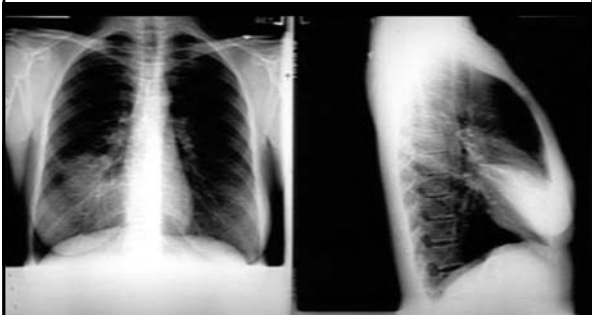---

---

---

---

---



Case 1

---

---

---

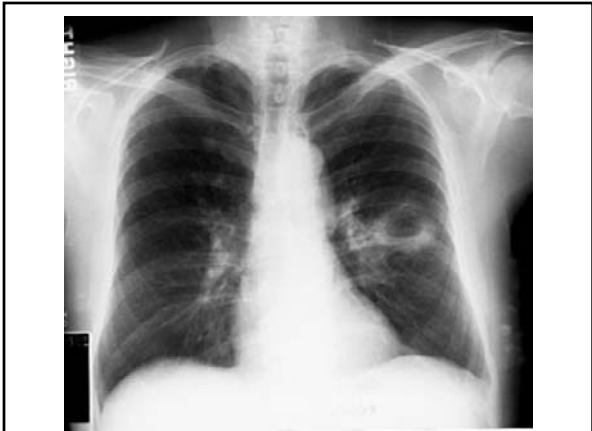---

---

---

---

---



Case 2

---

---

---

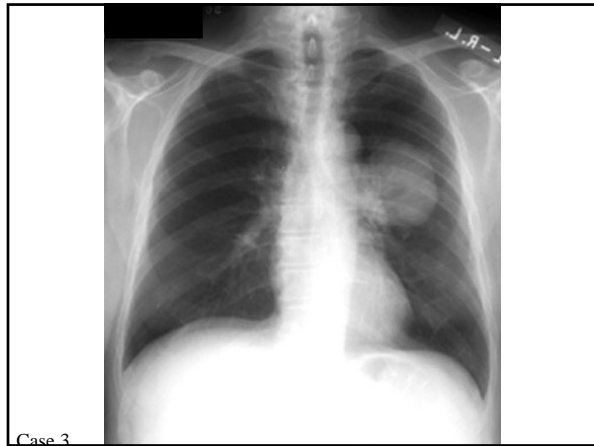---

---

---

---

---



Case 3

---

---

---

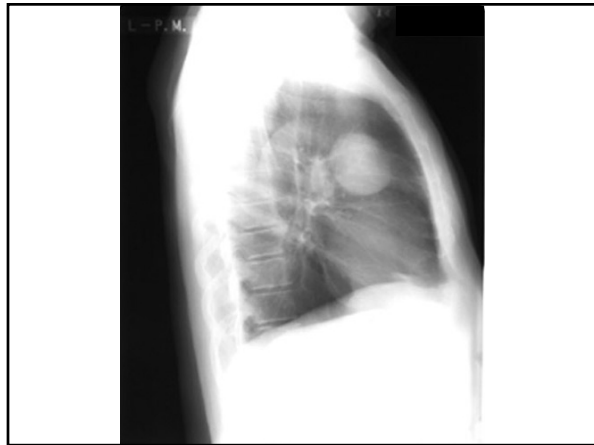
---

---

---

---

---



---

---

---

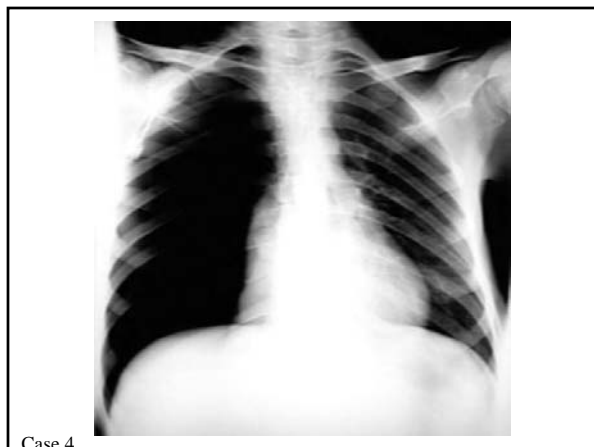---

---

---

---

---



Case 4

---

---

---

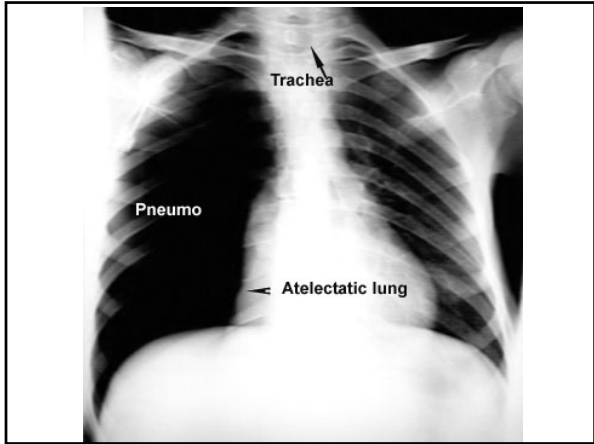
---

---

---

---

---



---

---

---

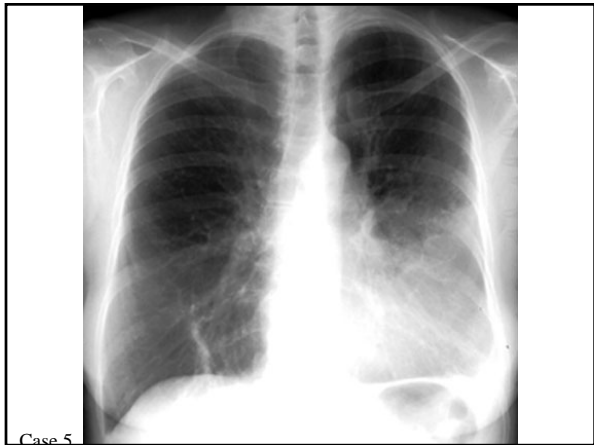---

---

---

---

---



---

---

---

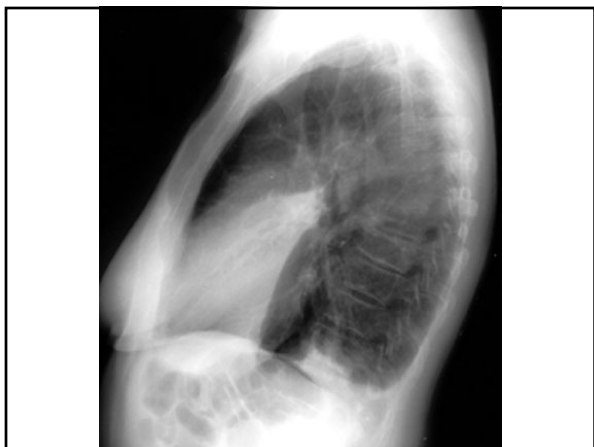---

---

---

---

---



---

---

---

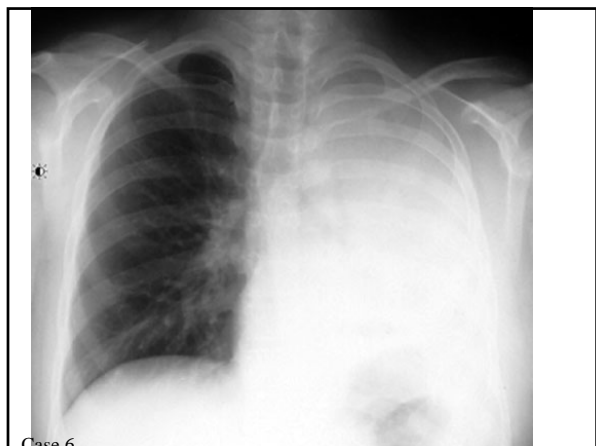
---

---

---

---

---



---

---

---

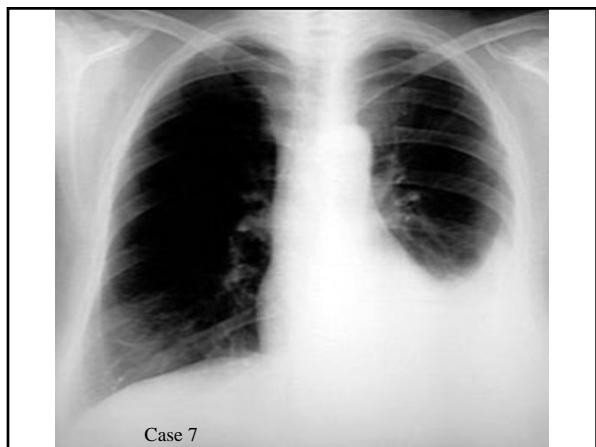
---

---

---

---

---



---

---

---

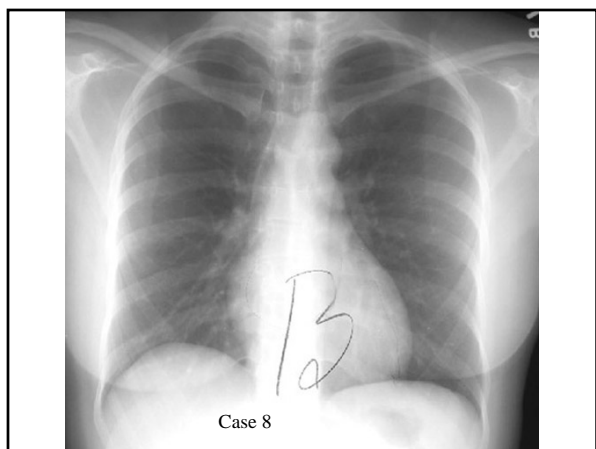
---

---

---

---

---



---

---

---

---

---

---

---

---