Normal Ob Gyne Ultrasound: Only the Basics

Jennifer Lim-Dunham, MD
Dept of Radiology
Loyola University Stritch School of Medicine

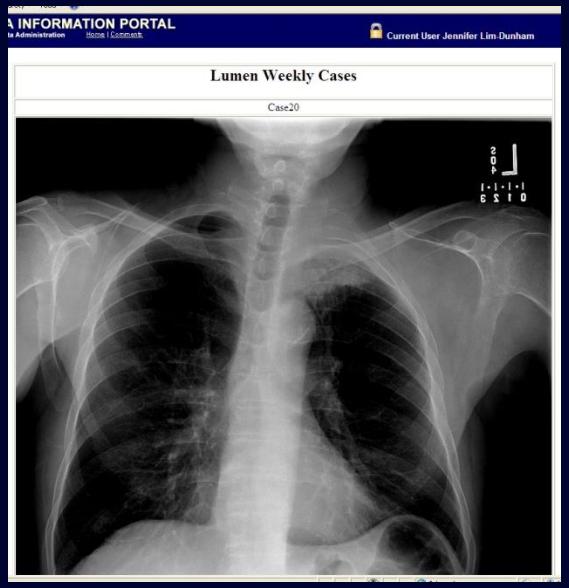
INFORMATION PORTAL
Current User Jennifer Lim-Dunham
Lumen Weekly Cases
Case20


INFORMATION PORTAL
Current User Jennifer Lim-Dunham
Patient presented with nagging left shoulder pain.
List all of the salient findings in this CXR?
What diagnosis are you considering?
Case Answer

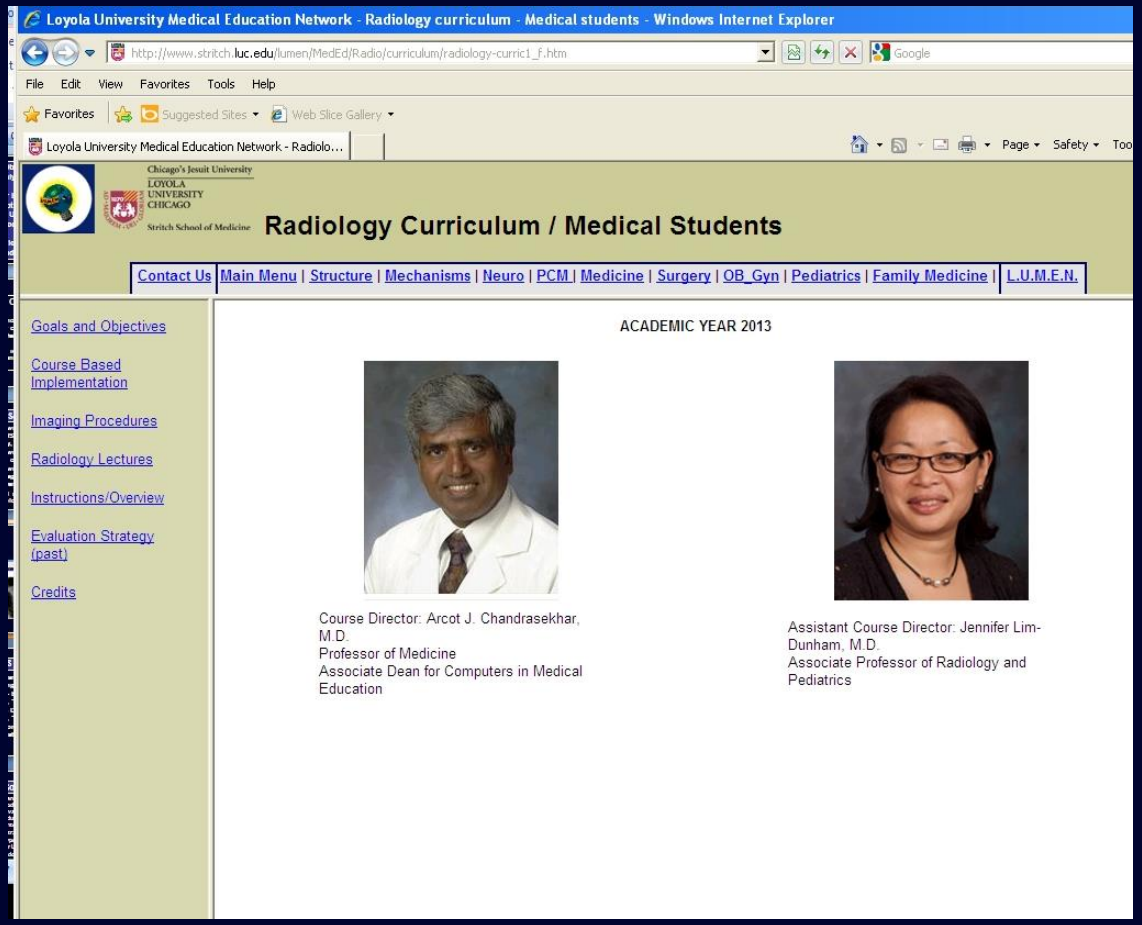
Loyola University Medical Education Network - Radiology curriculum - Medical students - Windows Internet Explorer
http://www.stritch.luc.edu/lumen/MedEd/Radio/curriculum/radiology-curric1_f.htm
File Edit View Favorites Tools Help
Favorites
Loyola University Medical Education Network - Radiolo...
Chicago's Jesuit University
LOYOLA UNIVERSITY CHICAGO
Stritch School of Medicine
Radiology Curriculum / Medical Students
Contact Us | Main Menu | Structure | Mechanisms | Neuro | PCM | Medicine | Surgery | OB_Gyn | Pediatrics | Family Medicine | L.U.M.E.N.
Goals and Objectives
Course Based Implementation
Imaging Procedures
Radiology Lectures
Instructions/Overview
Evaluation Strategy (past)
Credits
ACADEMIC YEAR 2013
Course Director: Arcot J. Chandrasekhar, M.D.
Professor of Medicine
Associate Dean for Computers in Medical Education
Assistant Course Director: Jennifer Lim-Dunham, M.D.
Associate Professor of Radiology and Pediatrics

Overview

Pelvic sonography is the imaging modality of choice for evaluating the female pelvis.

US uses NO ionizing radiation (which can cause cancer and birth defects in fetus)

GOALS&OBJECTIVES

- Be familiar with how US images are obtained, US image orientation, US terminology, how sound waves travel
- Be familiar with appearance of normal uterine and ovarian anatomy
- Be familiar with first and second trimester pregnancy normal appearance and measurements used for dating
- This is NOT intended to cover all Ob Gyne pathology

US terminology

Isoechoic- Same brightness as surrounding soft tissue structures

Hyperechoic- Brighter than surrounding soft tissue, “whiter”

Hypoechoic- Darker than surrounding soft tissue, “blacker”

Anechoic- Completely black, no echoes. This is what fluid looks like.

Sound waves

- Ultrasound transducer sends sound waves through the body. Sound waves are reflected differently by various types of tissue, and sent back to transducer where signal is transformed into visible image
- Sound waves travel through soft tissue or fluid. These types of structures are used as “windows” for US scanning
- Sound waves do not travel through and are reflected by air or bone (calcium), resulting in shadowing behind these structures

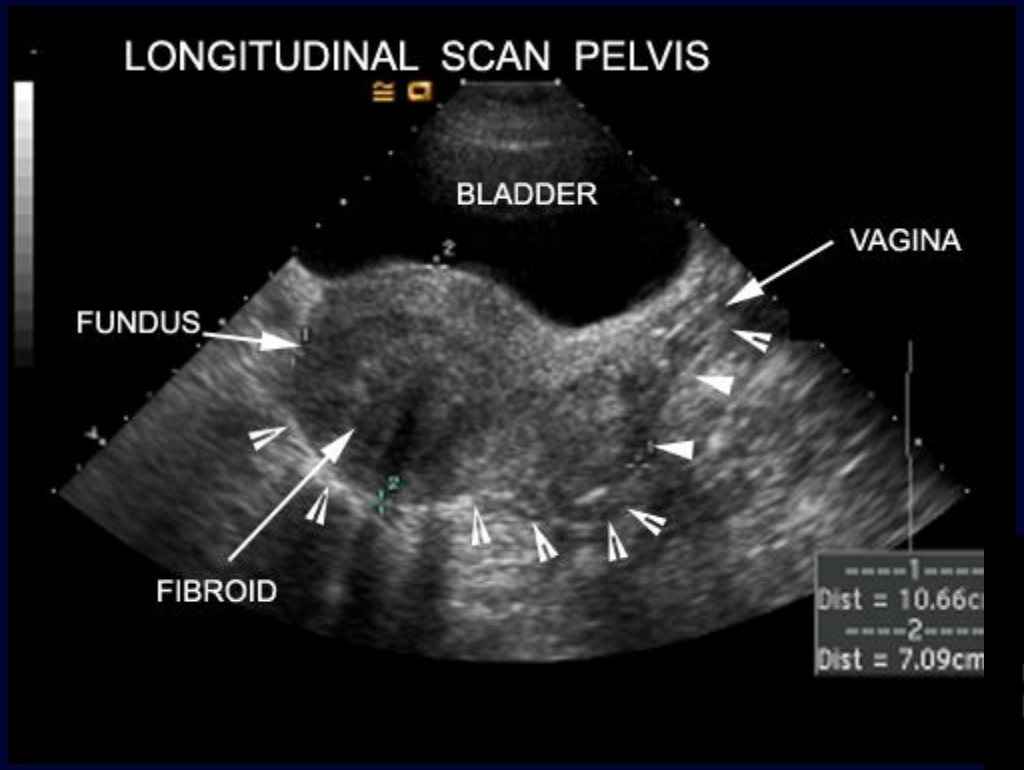
LONGITUDINAL SCAN PELVIS
BLADDER
VAGINA
FUNDUS
FIBROID
Dist = 10.66c
Dist = 7.09cm

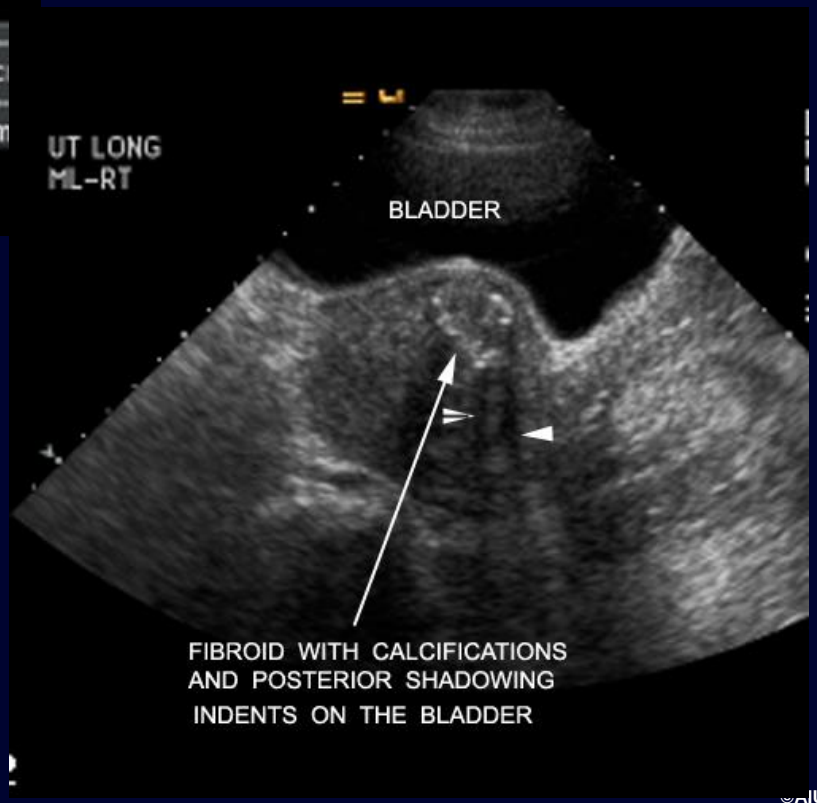
UT LONG
ML-RT
BLADDER
FIBROID WITH CALCIFICATIONS
AND POSTERIOR SHADOWING
INDENTS ON THE BLADDER

Technique

- The standard pelvic examination
  - Composed of the traditional transabdominal approach (TAS)
  - Combined with transvaginal sonography (TVS)
  - Frequently using Doppler sonography

Technique

- Transabdominal sonography uses a distended bladder as window to pelvic structures for a global view.

Transabdominal Sonography

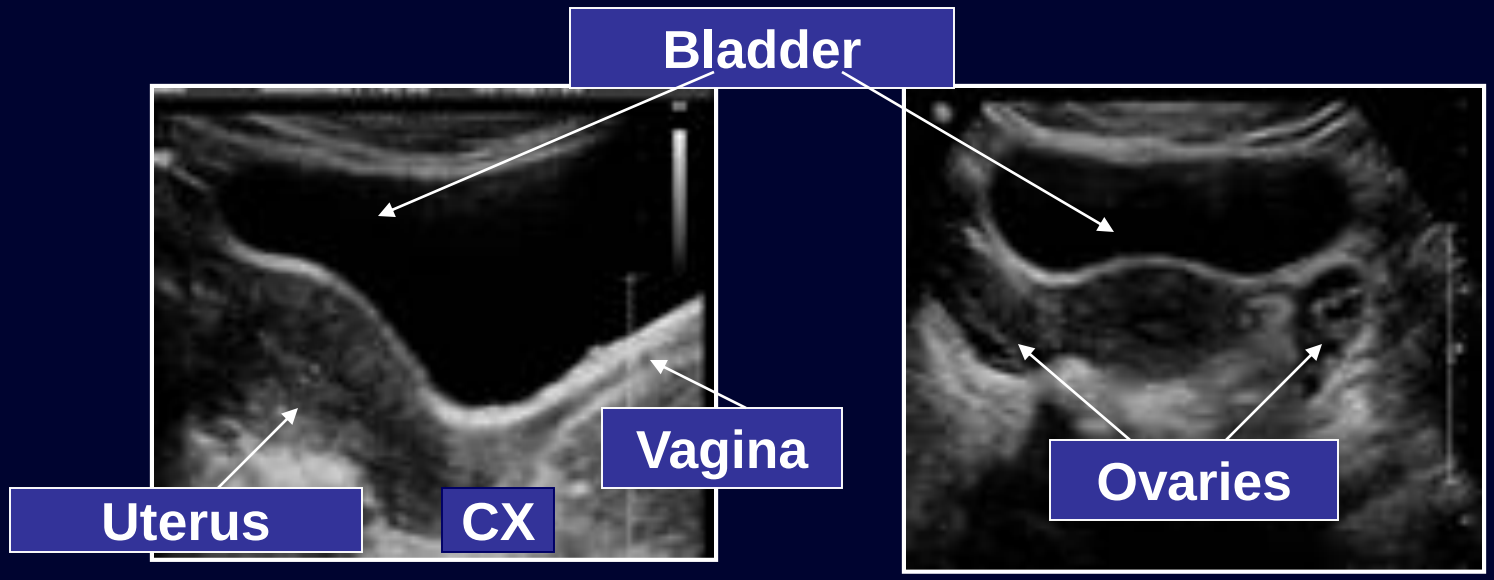

- Sagittal and transverse views of the pelvis
- Uterus on sagittal has “teardrop” appearance

Technique

- Transvaginal sonography gives a more detailed evaluation of pelvic architecture using higher-frequency transducers at closer proximity to pelvic structures.

Transvaginal Sonography

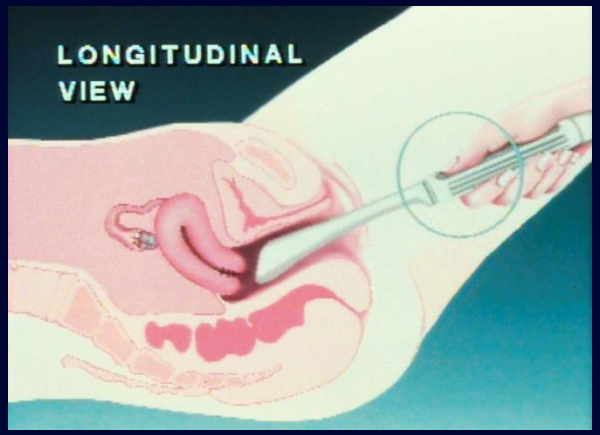

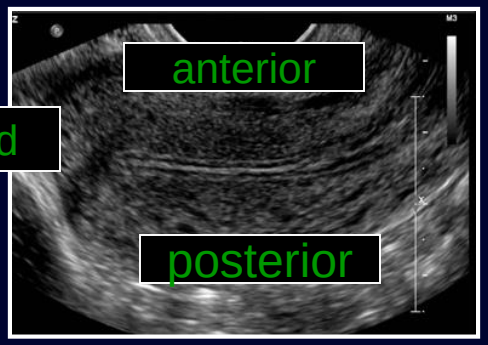

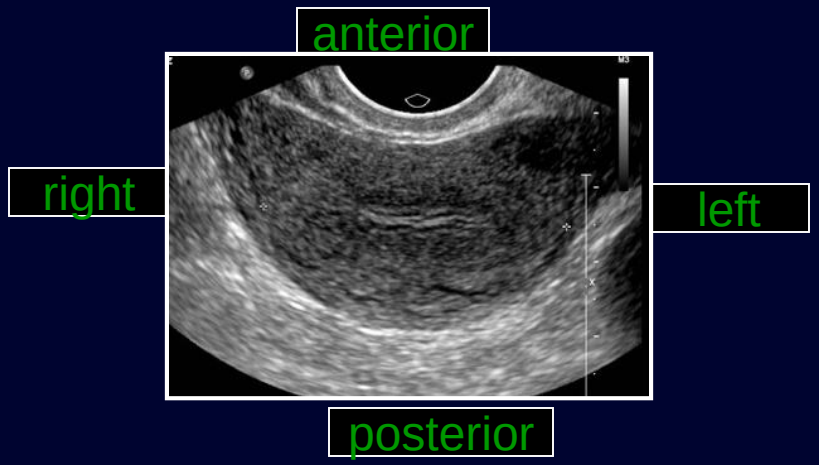

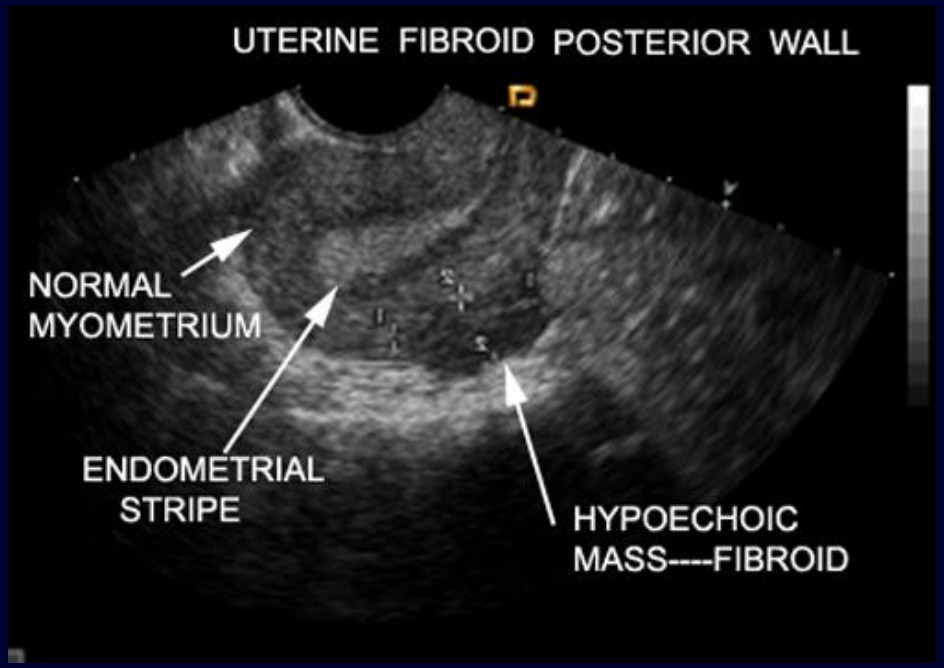

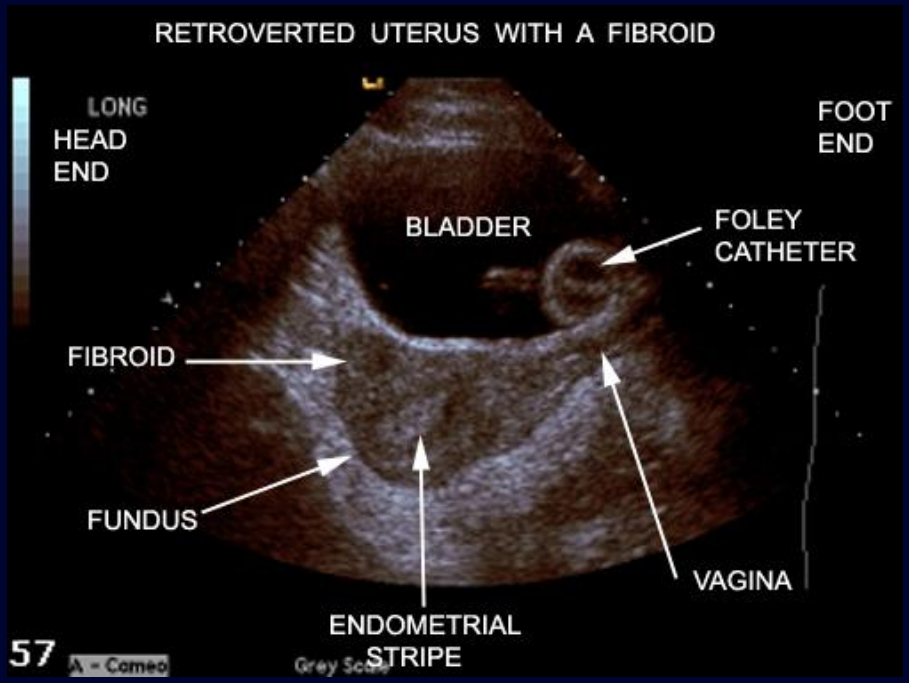

Transvaginal US

Transabdominal US

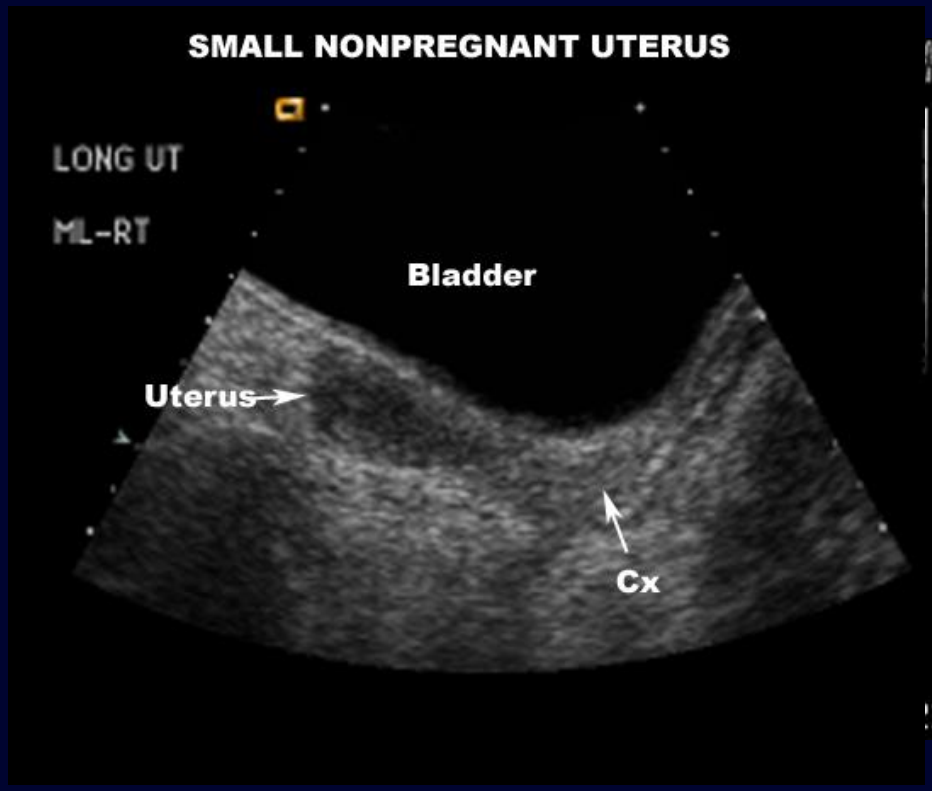

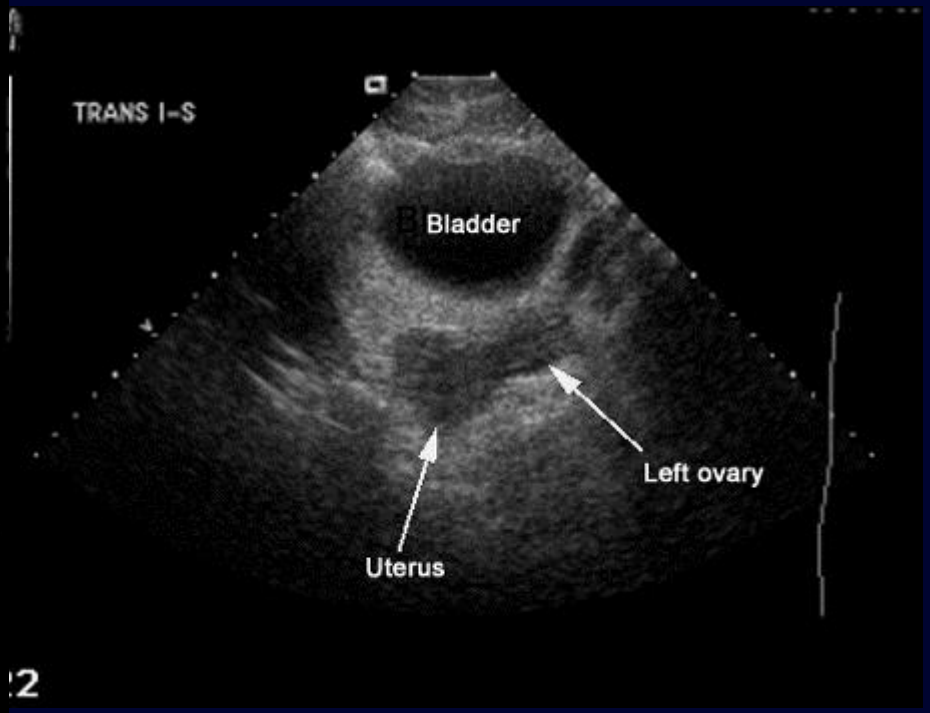

Use all the information from the labeling that you are given to orient yourself to anatomy

Long= longitudinal, usually sagittal relative to body. Convention: patient's head to left of screen.

Trans=transverse, usually axial relative to body. Convention: patient's right side to left of screen.

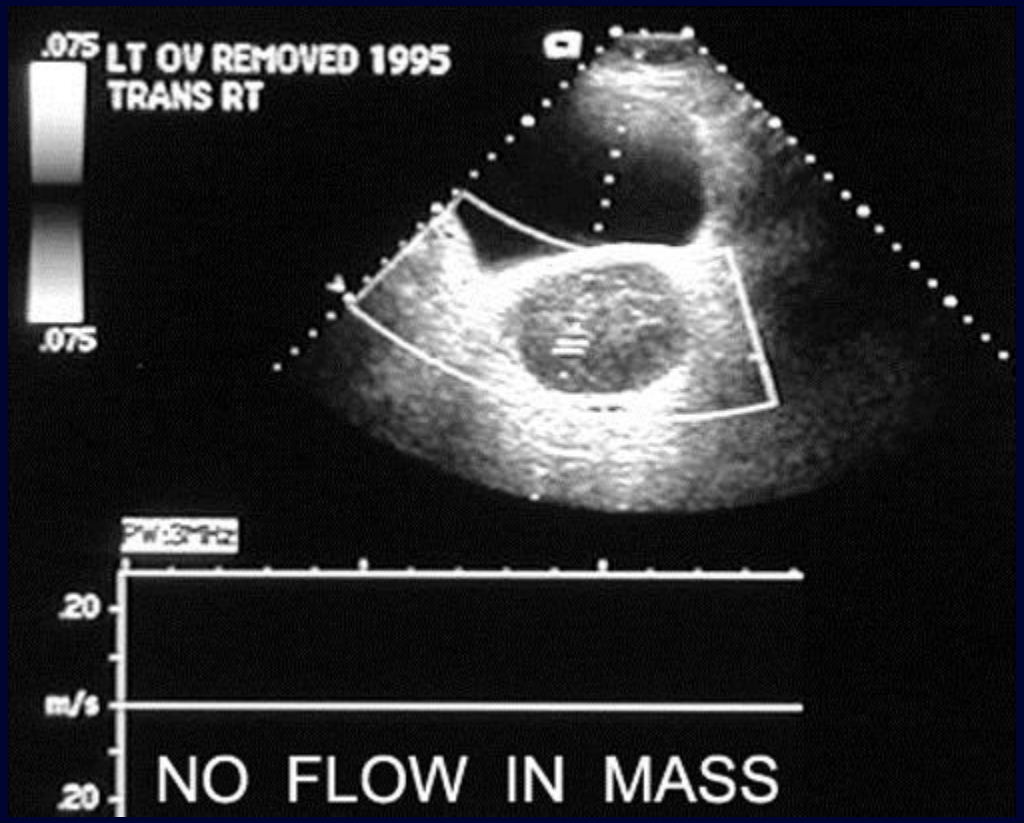

Use all the information from the labeling that you are given to orient yourself to anatomy and history

The Normal Sonographic Appearance of the Nongravid Genital Tract

Pelvis

Anatomy Pelvis

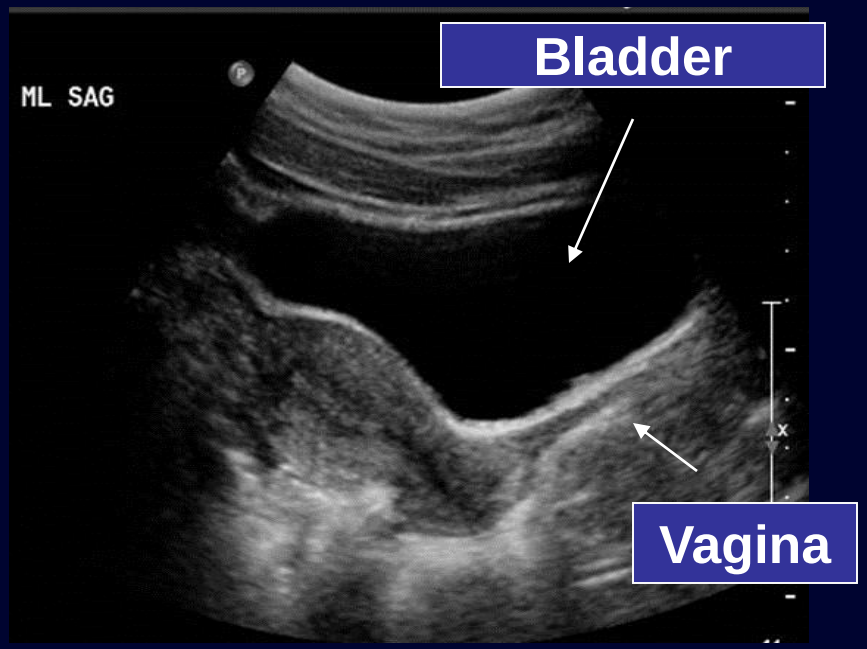

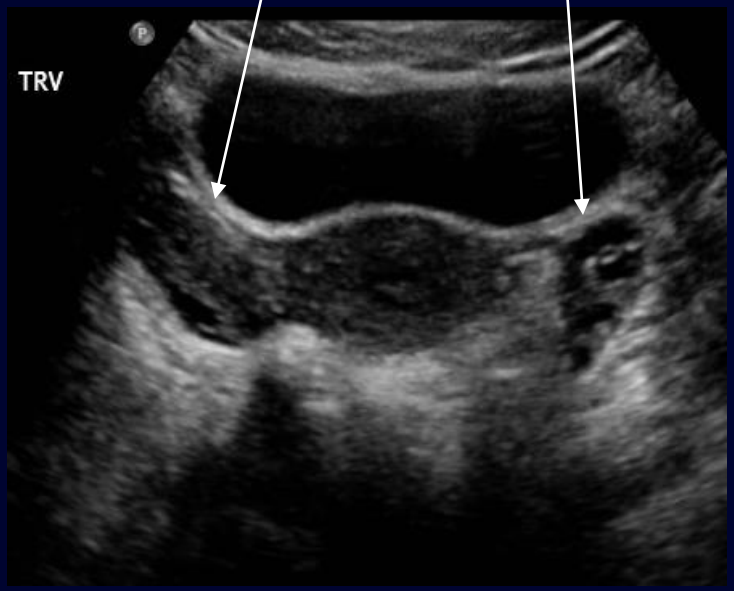

Uterus: cervix, body, fundus

Premenopausal Endometrium

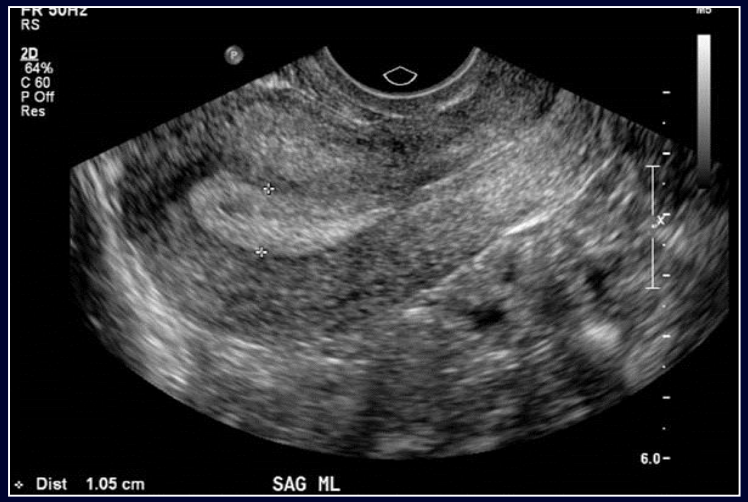

Proliferative

Secretory

Uterine anatomy: myometrium vs. endometrium

Ovary

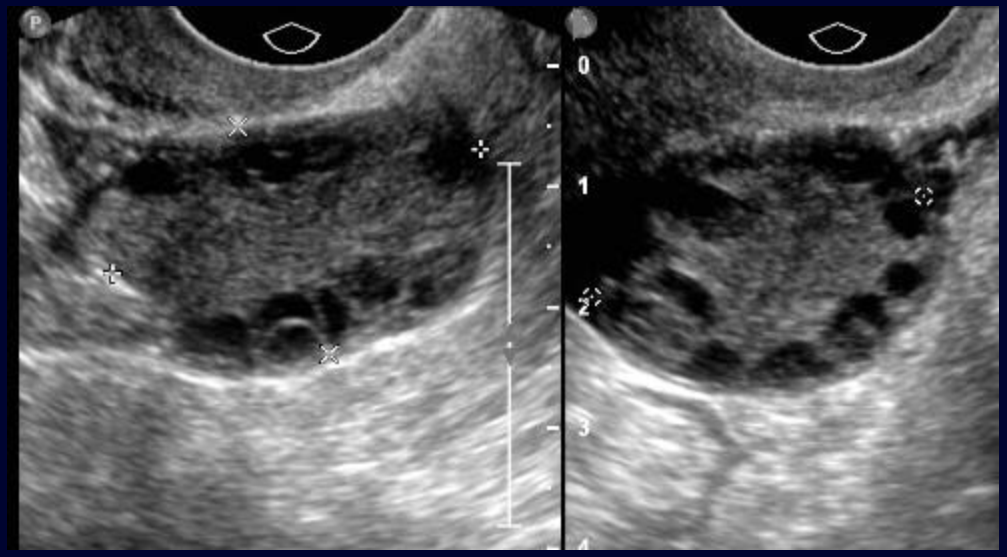

- **The ovaries are ellipsoid and can be identified in menstruating females by the presence of follicles.**

Cul-de-sac

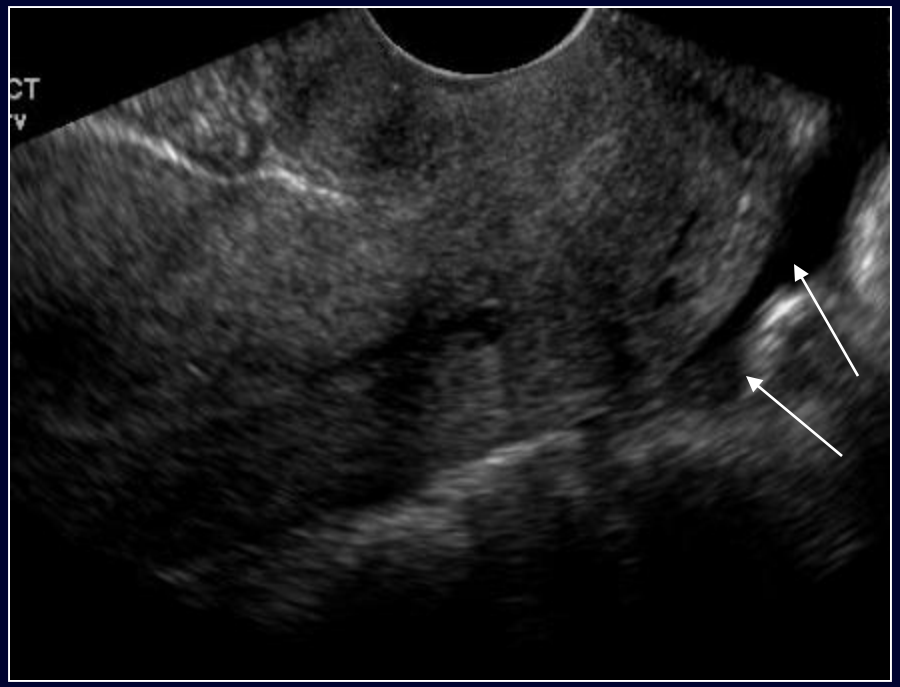

- Physiologic fluid in cul-de-sac

Basic obstetrical ultrasound

LMP? Pregnant?

- In the female in the reproductive years, the physiologic as well as the pathologic processes are driven by the menstrual cycle and hormonal stimulation.
- Therefore, know the day of your patients' day of the cycle, therefore…
- Know if your patient has a positive pregnancy test, and if so, what the quantitative serum beta hCG is.

Early Gestational Sac

- Decidualized endometrium = echogenic
- Early gestational sac 16-21 days after conception
- Yolk sac seen about 5 weeks

First Trimester

- By the 6th menstrual week, the early embryo can be identified.
  - Usually with cardiac activity
  - The crown-rump length (CRL) is the best estimation of GA once appears.

Second Trimester

- After 13-14 weeks, measurements used for dating are:
  biparietal diameter (BPD), head circumference (HC), abdominal circumference (AC), and femur length (FL)

Fetal dating: BPD biparietal diameter

BPD measured from outer to inner

Fetal dating: HC head circumference

Note: HC measured on the outside

Fetal dating: FL femur length

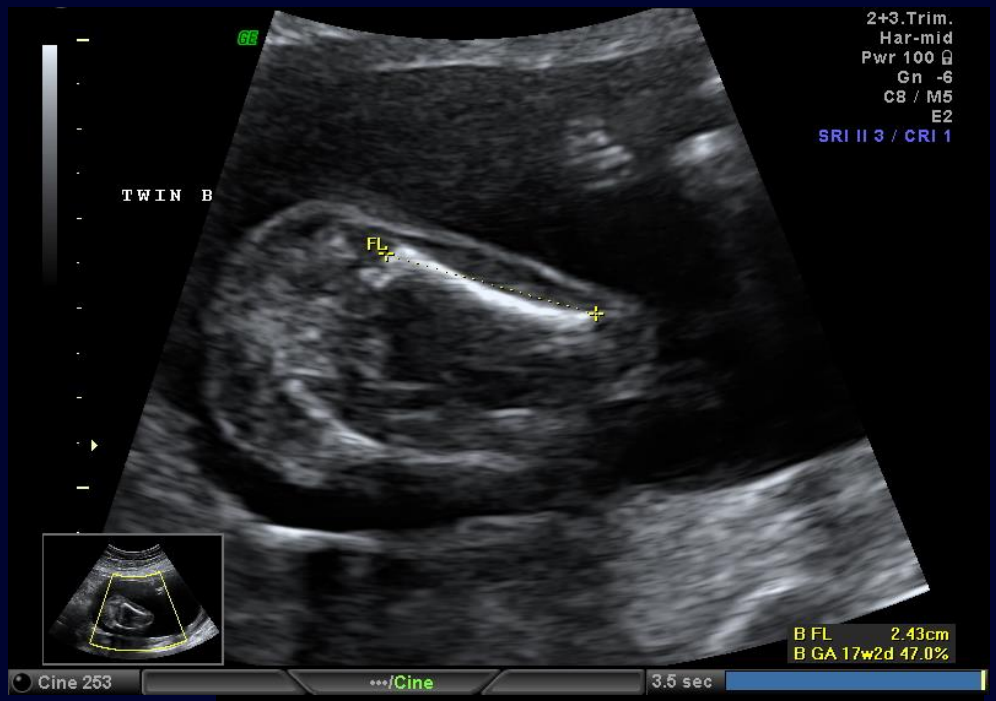

Only ossified bone is measured

Fetal dating: AC abdominal circumference

Note: AC is measured on outer circumference

Second Trimester

- Placenta

Placenta and cervix: placenta previa

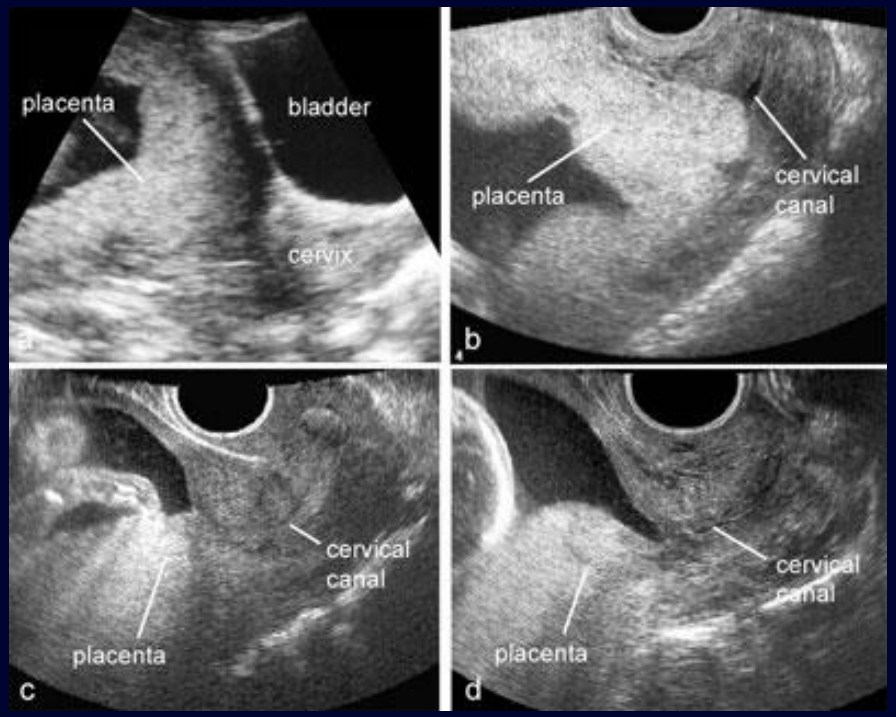

Example of Color and Spectral Doppler Ultrasound

- Flow to the transducer is shown in red and away in blue.
- The Doppler sample volume (oblique arrow) shows the sampling site for pulsed Doppler interrogation.
- The right panel shows spectral Doppler of umbilical artery flow. As the flow is toward the transducer, it is depicted as positive or upward deflections.

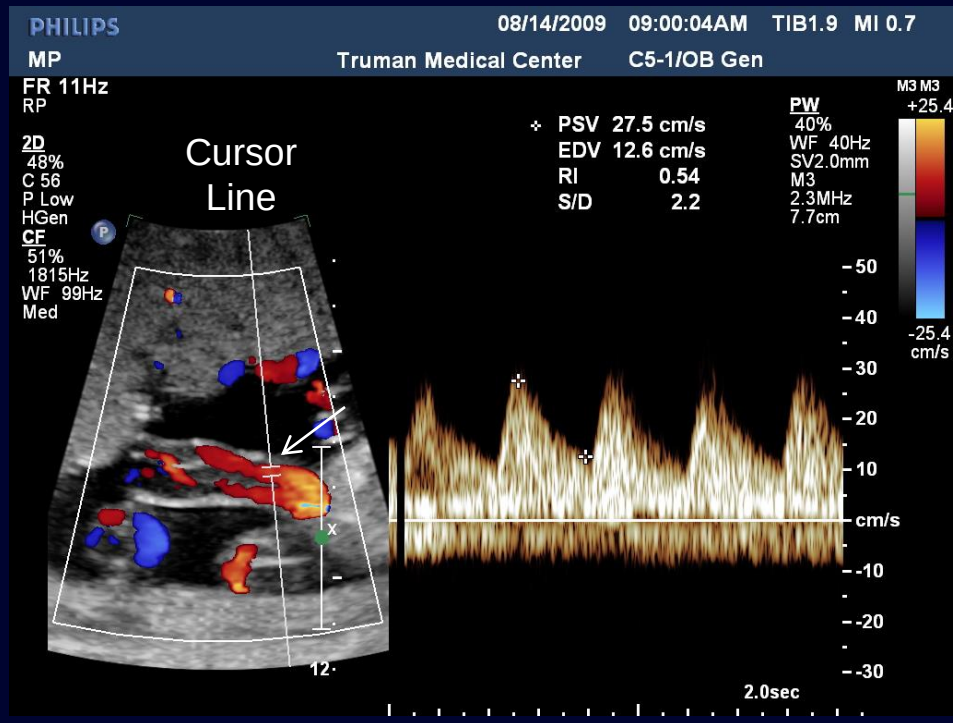

Umbilical artery Doppler waves

Take Home Points

- US is first line modality to examine female pelvis and gravid female pelvis
- US uses no ionizing radiation
- US uses sound waves, which travel best through soft tissue or fluid
- US can be performed transabdominally or transvaginally
- Conventional orientation for US images is used

Take Home Points

- Use terminology “hyperechoic” and “hypoechoic”
- Fluid is black or anechoic on US
- We reviewed appearance of normal uterine and ovarian anatomy
- We reviewed first and second trimester pregnancy normal appearance
- Measurements used for fetal dating: BPD, HC, AC, FL

Practice cases for students: Normal and abnormal

- Transabdominal, transvaginal or can't tell?
- Body part?
- Normal or abnormal (provide diagnosis or Ddx if possible)

Group 1

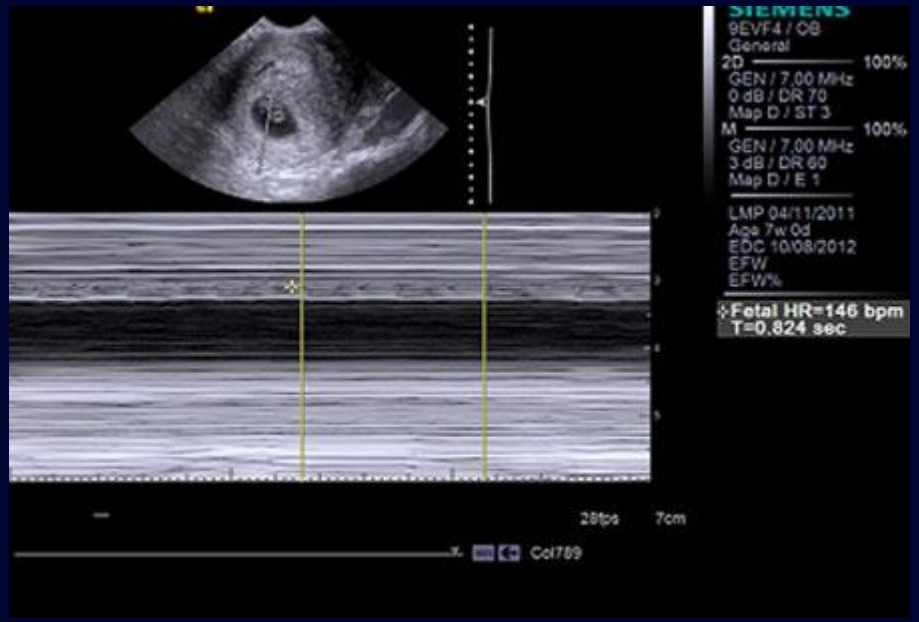
SIEMENS
9EVF4 / OB
General
2D 100%
GEN / 7.00 MHz
0 dB / DR 70
Map D / ST 3
M 100%
GEN / 7.00 MHz
3 dB / DR 60
Map D / E 1
LMP 04/11/2011
Age 7w 0d
EDC 10/08/2012
EFW
EFW%
Fetal HR=146 bpm
T=0.824 sec
28fps
7cm
Col789

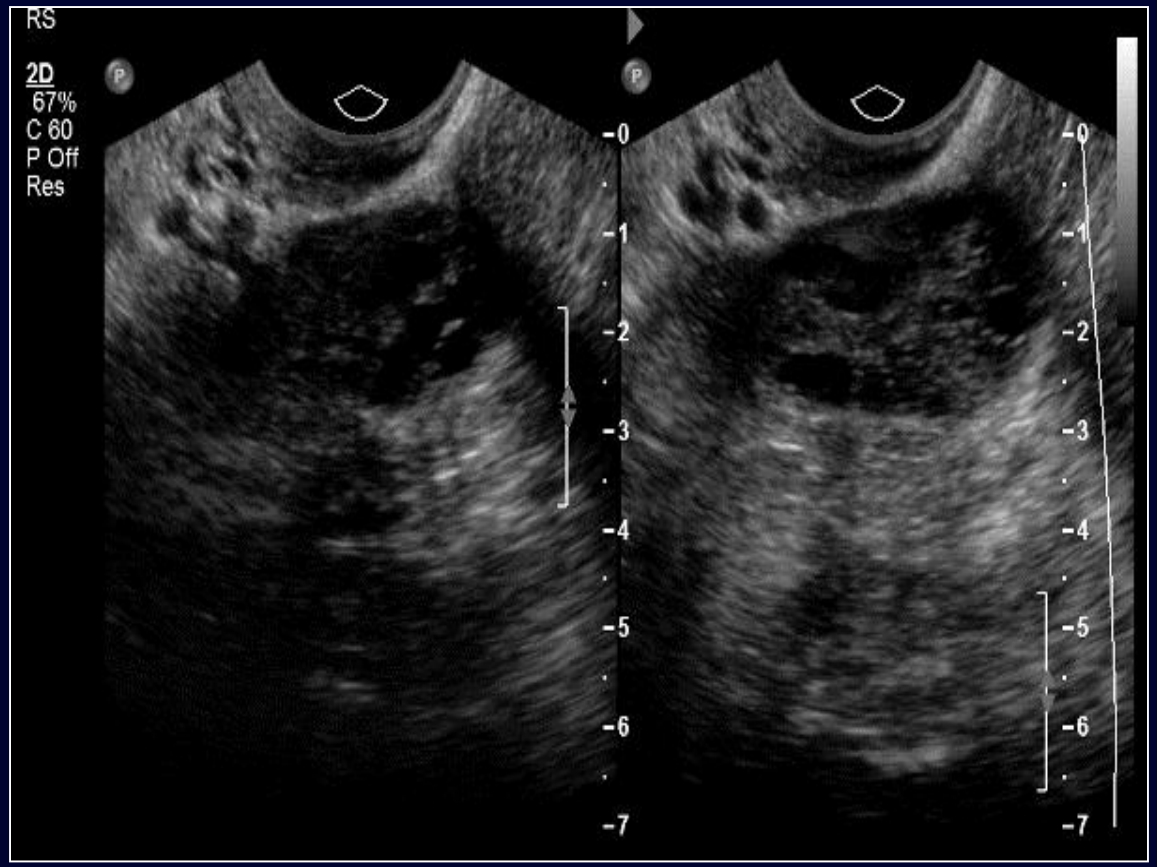

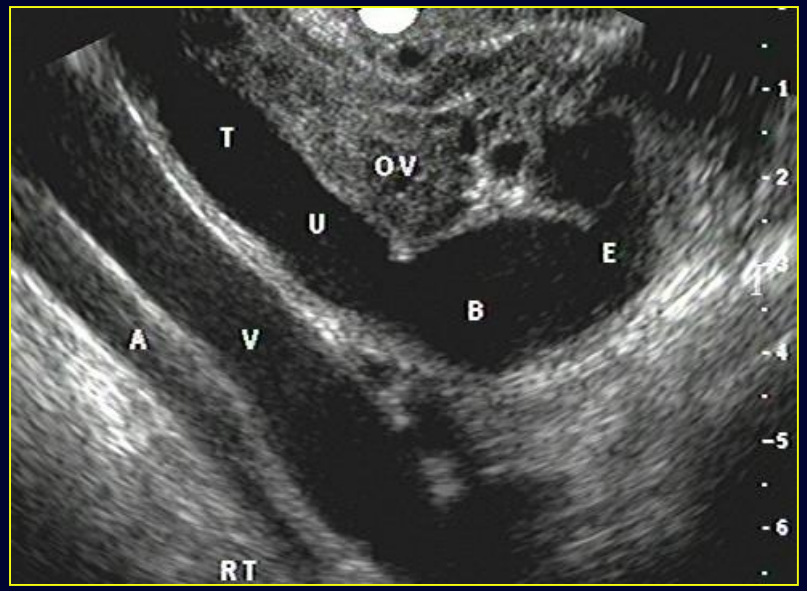

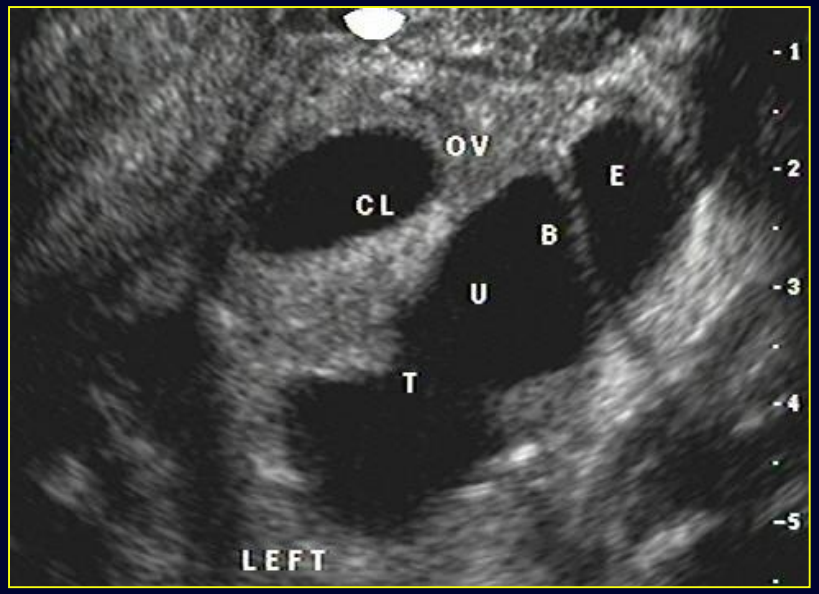

Group 2

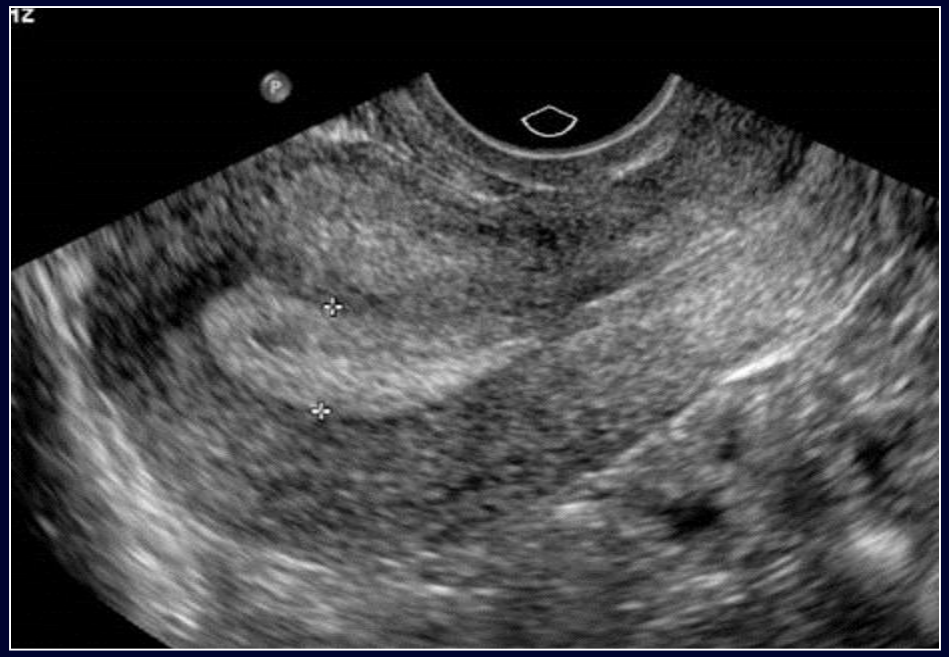

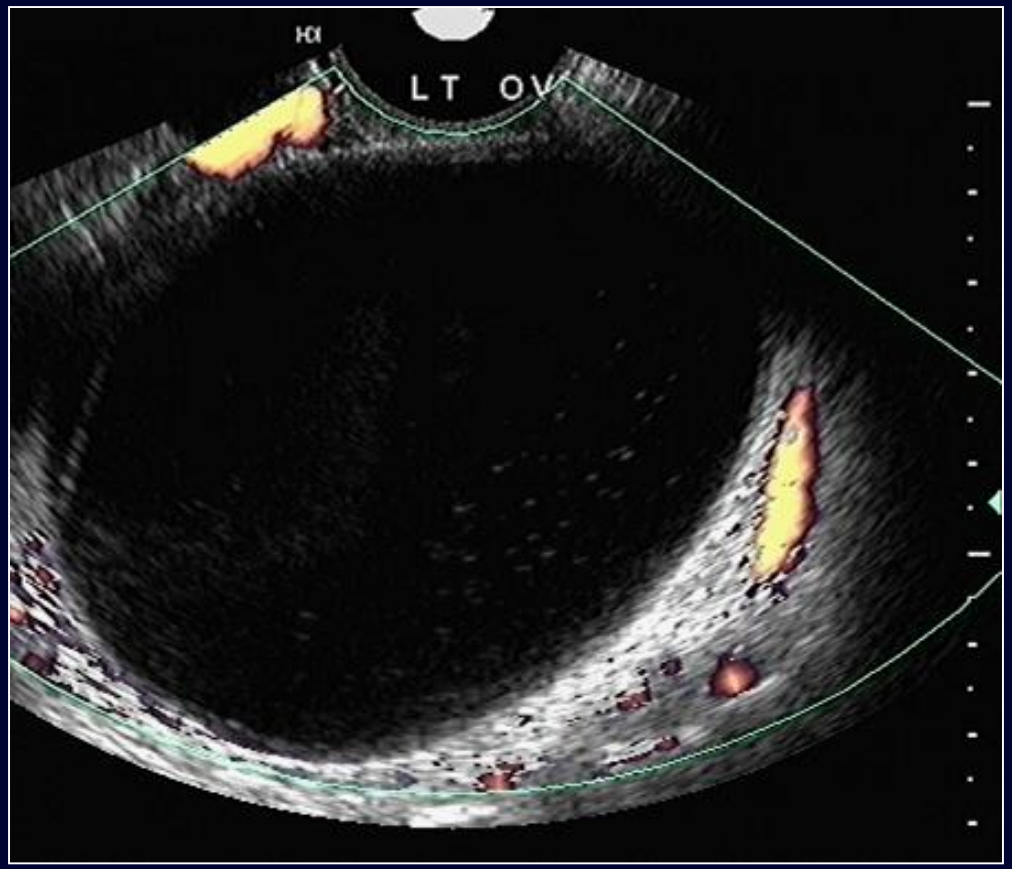

MRI

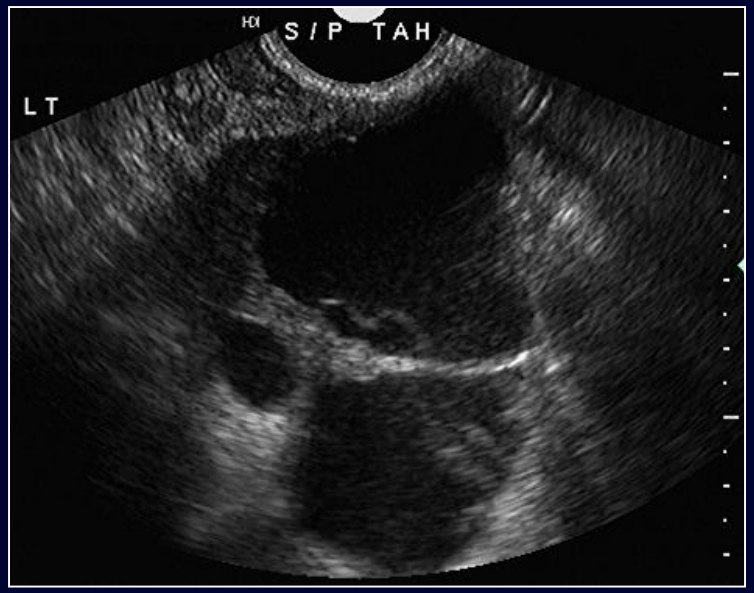

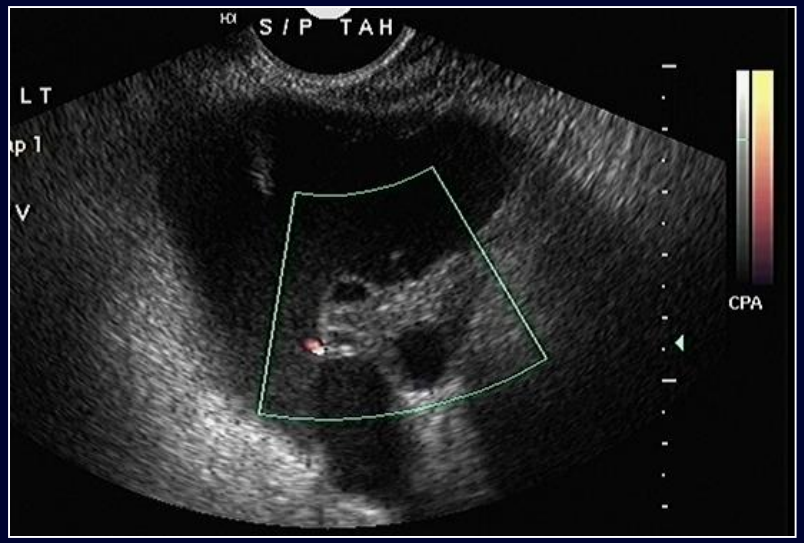

Group 3

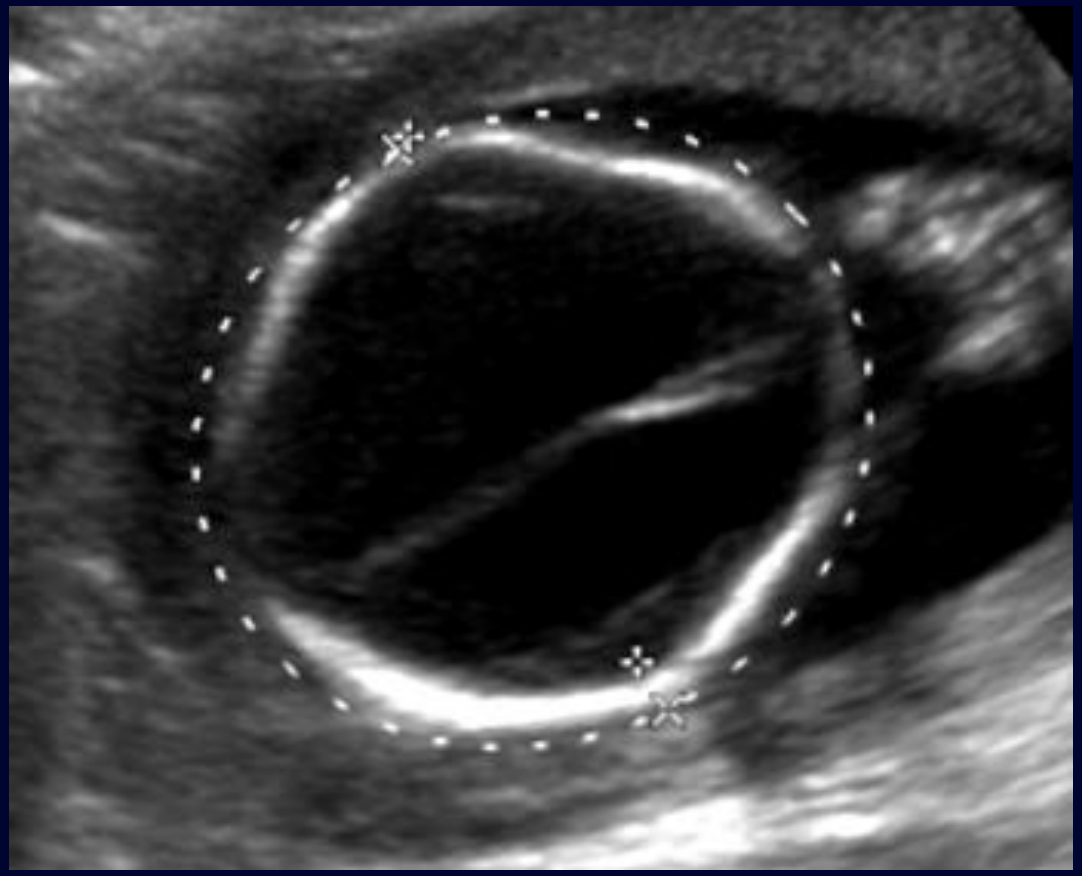

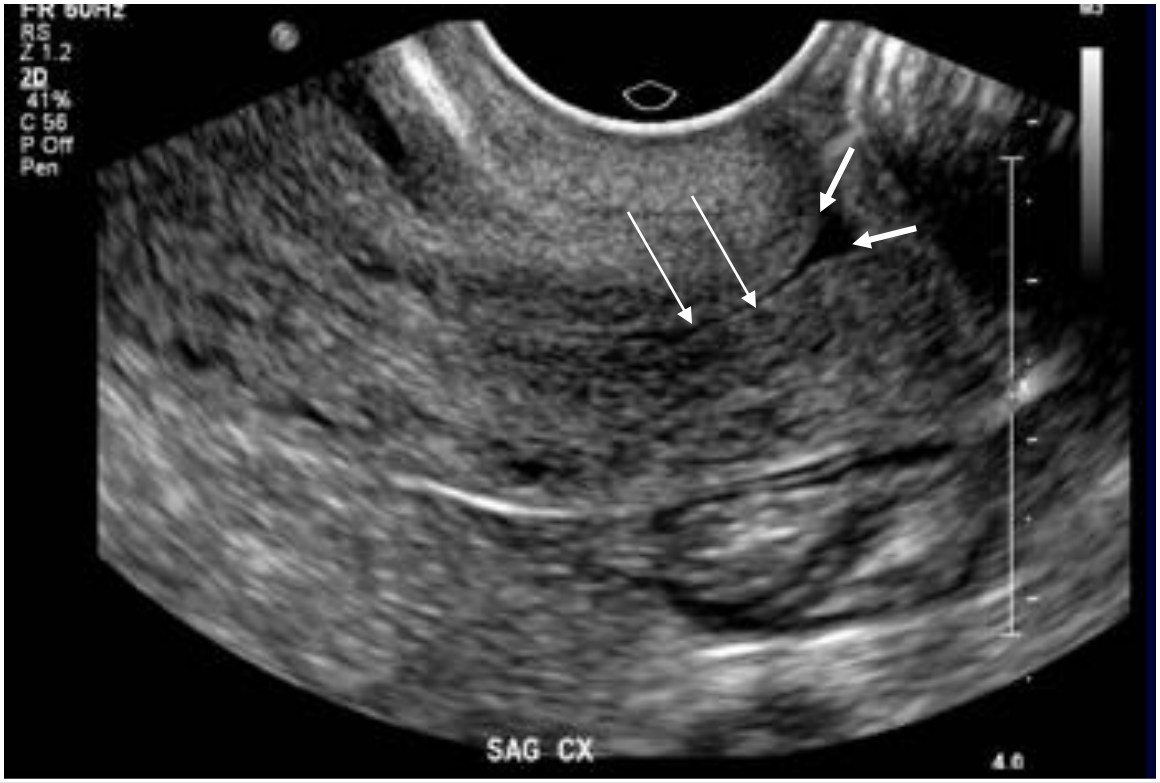

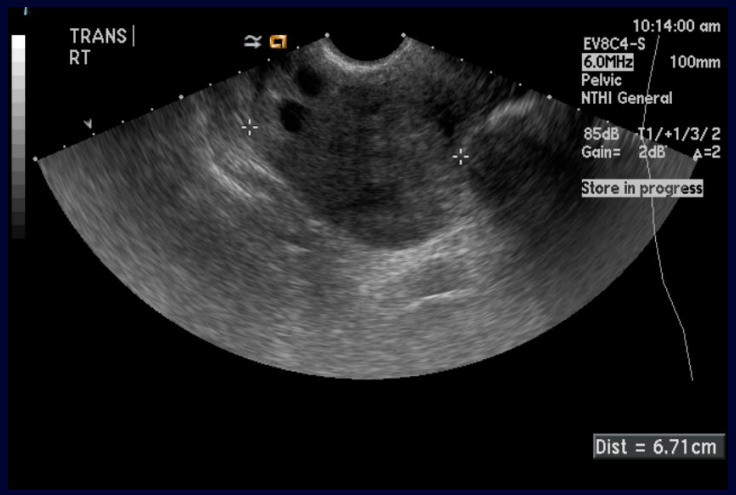
TRANS
RT
10:14:00 am
EV8C4-S
6.0MHz
100mm
Pelvic
NTHI General
85dB T1/+1/3/2
Gain= 2dB Δ=2
Store in progress
Dist = 6.71cm

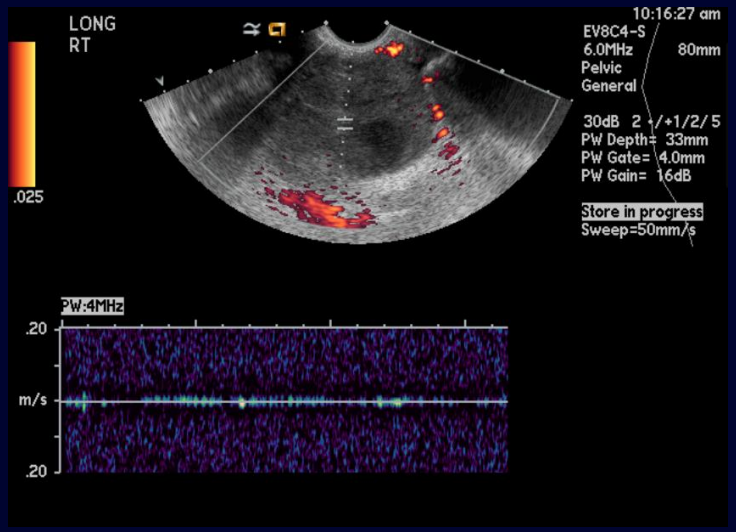
LONG
RT
10:16:27 am
EV8C4-S
6.0MHz
80mm
Pelvic
General
30dB 2 +/+1/2/5
PW Depth= 33mm
PW Gate= 4.0mm
PW Gain= 16dB
Store in progress
Sweep=50mm/s
.025
PW:4MHz
.20
m/s
.20

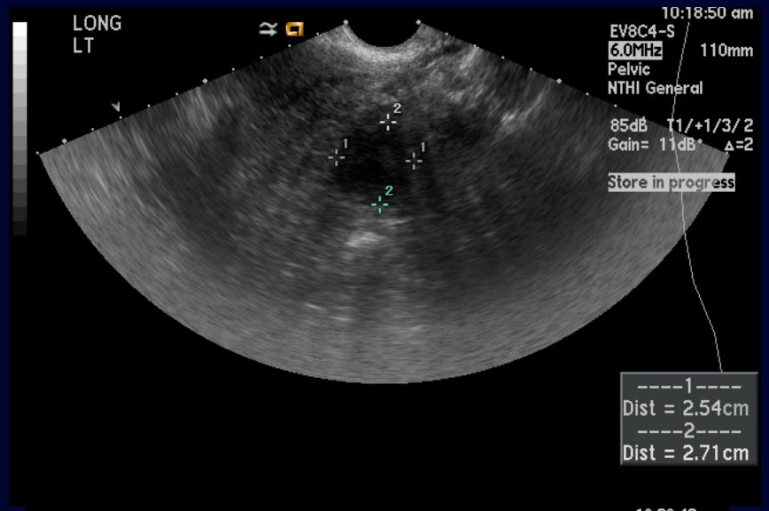
LONG
LT
10:18:50 am
EV8C4-S
6.0MHz
110mm
Pelvic
NTHI General
85dB T1/+1/3/2
Gain= 11dB Δ=2
Store in progress
----1----
Dist = 2.54cm
----2----
Dist = 2.71cm

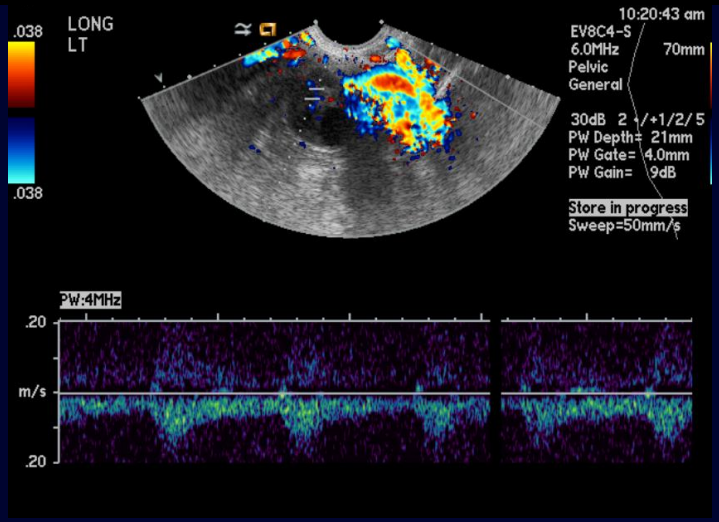
.038
LONG
LT
10:20:43 am
EV8C4-S
6.0MHz
70mm
Pelvic
General
30dB 2 +/+1/2/5
PW Depth= 21mm
PW Gate= 4.0mm
PW Gain= 9dB
Store in progress
Sweep=50mm/s
.038
PW:4MHz
.20
m/s
.20