

Internal Medicine Clerkship
Case Discussions

Venous Thromboembolic Disease
Student Guide

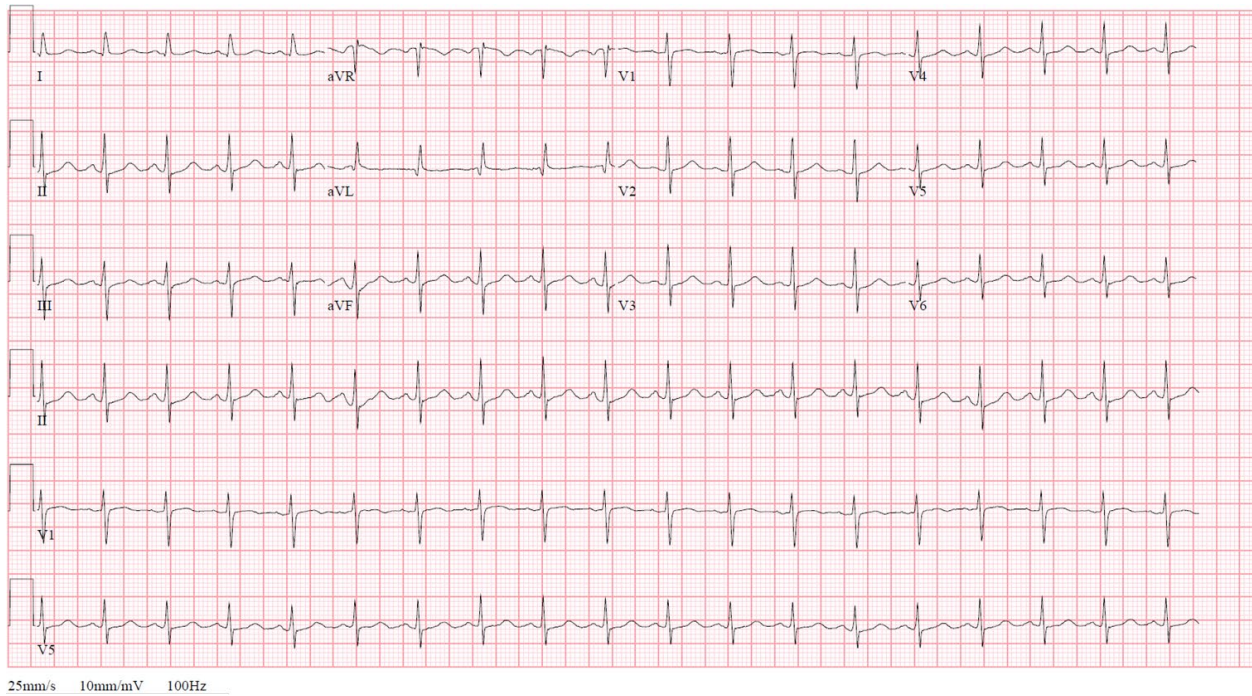
Objectives:

1. Identify characteristics and relevant review of systems that may suggest a venous thromboembolism including leg pain and swelling, chest pain, and shortness of breath.
2. Assess past medical history for risk factors and predisposing conditions including prior VTE, bleeding or clotting disorders, and causative medications.
3. Assess for familial risk factors including family history of bleeding or clotting disorders.
4. Identify key physical exam findings that:
 - a. Determine severity of disease including tachycardia and hypotension.
 - b. Assess for findings that may suggest an underlying etiology including leg pain or swelling and findings of venous insufficiency.
 - c. Determine presence of right heart failure including elevated jugular venous pressure.
5. Identify and interpret key laboratory and imaging tests and list indications, benefits, test characteristics, risks, and costs of testing that assess extent of thrombosis (including compression ultrasonography and CT angiogram) and assess severity of illness (including ABG and echocardiogram).
6. Describe a rational and evidence-based approach to treating a patient with venous thromboembolic disease:
 - a. Use a validated clinical risk score to establish pre-test probability for DVT or PE (Wells score).
 - b. Describe treatment for thrombosis including direct-acting oral anticoagulant medications, low molecular weight heparin, and thrombolysis.
 - c. Describe treatment for hemodynamic instability including oxygenation and fluid resuscitation.

Clinical Case:

A 35 year old female reports to the emergency room because of sharp left-sided chest pain and shortness of breath for the past day. The patient was in excellent health until yesterday. She was awakened from sleep by the sharp left-sided chest pain. The pain worsened with motion and deep breathing. The pain has been increasing in severity and now she has severe left shoulder pain. She reveals having a similar, transient episode of chest pain about one year ago while she was vacationing in Michigan. Presently, she complains of shortness of breath and is very apprehensive about dying. She denies any cough, fever, or sputum production, but has had one episode of hemoptysis earlier today and, upon further questioning, notes some tenderness of the left calf. She is married and had one normal delivery three years ago. She is taking birth control pills. She has never been hospitalized except for delivery of her first child. The patient does recall having a left ankle fracture 6 years ago with a cast in place for 6 weeks. A review of systems is negative. She denies any history of venous problems. She works as a computer programmer. She has smoked one pack of cigarettes a day for the past eight years. She considers herself a social drinker. There is no family history of blood clots.

EKG:

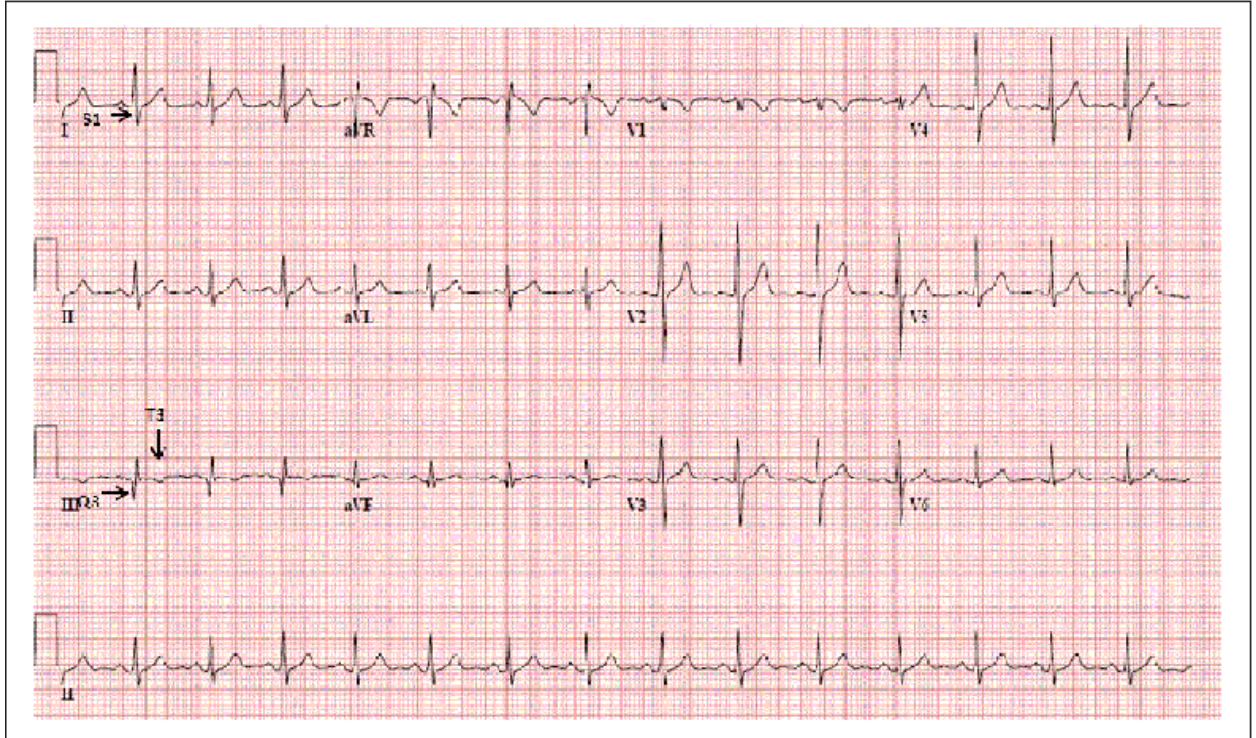


Questions:

5. Interpret the arterial blood gas: 7.48/30/80.

6. What acid base abnormality would you expect with an acute PE?

7. Interpret the EKG. Are there any EKG patterns that could suggest PE as a diagnosis?

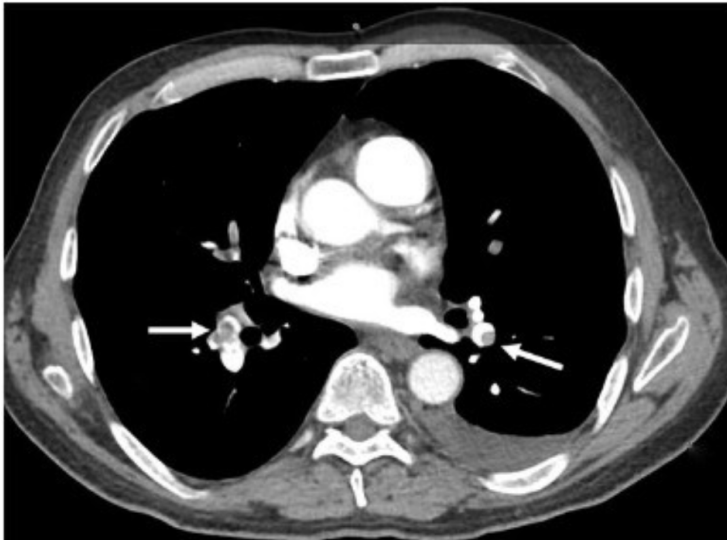


8. What is your pre-test probability that she has a PE?

9. The following are tests that can be ordered for evaluation of patients with suspected acute PE. Describe a scenario when each test would be appropriate and which test should be ordered on our patient?
 - a. D-dimer
 - b. CT-PE protocol
 - c. VQ scan
 - d. Lower extremity ultrasound
 - e. Echocardiogram

10. How are VQ scans reported when considering pulmonary embolism?

CTA is completed:



Questions:

11. Interpret the CT findings. Does something explain the patient's left shoulder pain?

12. The following are options for treatment of acute PE/DVT. Explain when each treatment option would be appropriate and which would you choose for our patient?
 - a. Heparin drip:
 - b. Low molecular weight heparin (LMWH):
 - c. Vitamin K antagonist (Warfarin)
 - d. Rivaroxaban (Xarelto):
 - e. Dabigatran (Pradaxa):
 - f. Aspirin :

13. Define the acute PE categories A-E based on the AHA 2026 guideline update.

14. Should this patient be admitted?

15. How long should outpatient therapy be maintained? Fill in the "recommended duration of anticoagulation" for each of the VTEs mentioned below:

16. What treatment would you suggest in the following scenarios?

- A. Systemic Thrombolysis
- B. Catheter-directed thrombolysis
- C. Systemic Anticoagulation

<ul style="list-style-type: none"> • BP 140/85, HR 100, RR, 30, O2 sat 92% on room air, mild respiratory distress. Saddle embolus found on CTA chest. 	C
<ul style="list-style-type: none"> • BP 70/45, HR 140, RR 32, O2 sat 90% on NRB. PE noted on CTA. Echo shows RV strain, troponin and BNP elevated. 	A
<ul style="list-style-type: none"> • BP 70/45, HR 140, RR 32, O2 90% on NRB. PE noted on CTA. Echo shows RV strain, troponin and BNP elevated. Hx of multiple GI bleeds requiring ICU stay, most recently 2 weeks ago. 	B
<ul style="list-style-type: none"> • BP 120/80, HR 90, RR 25, O2 93% on RA. Multiple PEs noted bilaterally on CT. Troponin +, BNP elevated, right heart strain on echo. 	C
<ul style="list-style-type: none"> • BP 128/70, HR 95, RR 22, O2 92% on RA on admission. Large PE in R main pulmonary artery. Patient started on lovenox and admitted. On hospital day #2, patient is more hypoxic with BP now 100/70, HR 110, RR 30 and O2 sat 92% on NRB. Troponin is now elevated 	A

- **The following may also prompt the use of systemic thrombolytic therapy:**
 - Deterioration that has not resulted in hypotension but:
 - progressive increase in heart rate
 - a decrease in systolic BP (which remains >90 mm Hg)
 - worsening gas exchange
 - signs of organ dysfunction (reduced urine output, confusion)
 - progressive right heart dysfunction on echocardiography
 - an increase in cardiac biomarkers

17. Should she also have an IVC filter placed prior to discharge?

References:

Creager MA, Barnes GD, Giri J, Mukherjee D, Jones WS, Burnett AE, Carman T, Casanegra AI, Castellucci LA, Clark SM, Cushman M, de Wit K, Eaves JM, Fang MC, Goldberg JB, Henkin S, Johnston-Cox H, Kadavath S, Kadian-Dodov D, Keeling WB, Klein AJP, Li J, McDaniel MC, Moores LK, Piazza G, Prenger KS, Pugliese SC, Ranade M, Rosovsky RP, Russo F, Secemsky EA, Sista AK, Tefera L, Weinberg I, Westafer LM, Young MN. 2026 AHA/ACC/ACCP/ACEP/CHEST/SCAI/SHM/SIR/SVM/SVN guideline for the evaluation and management of acute pulmonary embolism in adults: a report of the American College of Cardiology/American Heart Association Joint Committee on Clinical Practice Guidelines. *Circulation*. 2026;153:e•••–e•••. doi: 10.1161/CIR.0000000000001415 <https://www.ahajournals.org/doi/10.1161/CIR.0000000000001415#sec-6>

Kahn SR, de Wit K. Pulmonary Embolism. *N Engl J Med*. 2022 Jul 7;387(1):45-57. doi: 10.1056/NEJMcp2116489. PMID: 35793208.

<https://www-nejm-org.archer.luc.edu/doi/10.1056/NEJMcp2116489>

Antithrombotic Therapy for VTE Disease; Second Update of the CHEST Guideline and Expert Panel Report. *Chest* 2021; 160(6):e545-e608.

<https://www-sciencedirect-com.archer.luc.edu/science/article/pii/S0012369221015063>

American Society of Hematology 2021 guidelines for management of venous thromboembolism: prevention and treatment in patients with cancer. *Blood Adv* (2021) 5 (4): 927–974.

<https://ashpublications.org/bloodadvances/article/5/4/927/475194/American-Society-of-Hematology-2021-guidelines-for>

American Society of Hematology 2020 guidelines for management of venous thromboembolism: treatment of deep vein thrombosis and pulmonary embolism. *Blood Adv* (2020) 4 (19): 4693–4738.

<https://www-clinicalkey-com.archer.luc.edu#!/content/playContent/1-s2.0-S2473952920312039?returnurl=null&referrer=null>

Righini M, et al. Age-adjusted D-dimer cutoff levels to rule out pulmonary embolism: the ADJUST-PE study. *JAMA*. 2014 Mar 19;311(11):1117-24. PMID: 24643601

<https://jamanetwork.com/journals/jama/fullarticle/1841967>

Harrison's Principles of Internal Medicine, 22e. Chapter 290: Deep Venous Thrombosis and Pulmonary Thromboembolism

<https://accessmedicine-mhmedical-com.archer.luc.edu/content.aspx?bookid=3541§ionid=296166046>

Harrison's Principles of Internal Medicine, 22e. Chapter 122: Arterial and Venous Thrombosis

<https://accessmedicine-mhmedical-com.archer.luc.edu/content.aspx?bookid=3541§ionid=294353026>

Symptom to Diagnosis: An Evidence-Based Guide, 4e. Chapter 15-11: Pulmonary Embolism

<https://accessmedicine-mhmedical-com.archer.luc.edu/content.aspx?bookid=2715§ionid=249059853>