

# ABDOMINAL ULTRASOUND

## Workshop:

**Location:** SSOM, L71

## Watch:

- **Liver Ultrasound Scanning Protocol: (6:24)**  
[https://www.youtube.com/watch?v=RCPO3qj7r\\_s&list=PLGEKJJ3ekUkyGrgO5kcpfbygn-klvdEit&index=1](https://www.youtube.com/watch?v=RCPO3qj7r_s&list=PLGEKJJ3ekUkyGrgO5kcpfbygn-klvdEit&index=1)
- **Spleen Ultrasound Scanning Protocol: (1:53)**  
[https://www.youtube.com/watch?v=gG191Gl\\_4ME&index=2&list=PLGEKJJ3ekUkyGrgO5kcpfbygn-klvdEit](https://www.youtube.com/watch?v=gG191Gl_4ME&index=2&list=PLGEKJJ3ekUkyGrgO5kcpfbygn-klvdEit)
- **Renal Ultrasound Scanning Protocol: (2:43)**
  - **Right (1:53)** <https://www.youtube.com/watch?v=AH8RcdMQMHA>
  - **Left (2:07)** <https://www.youtube.com/watch?v=zvOm9XDV02s>

## ***LEARNING OBJECTIVES***

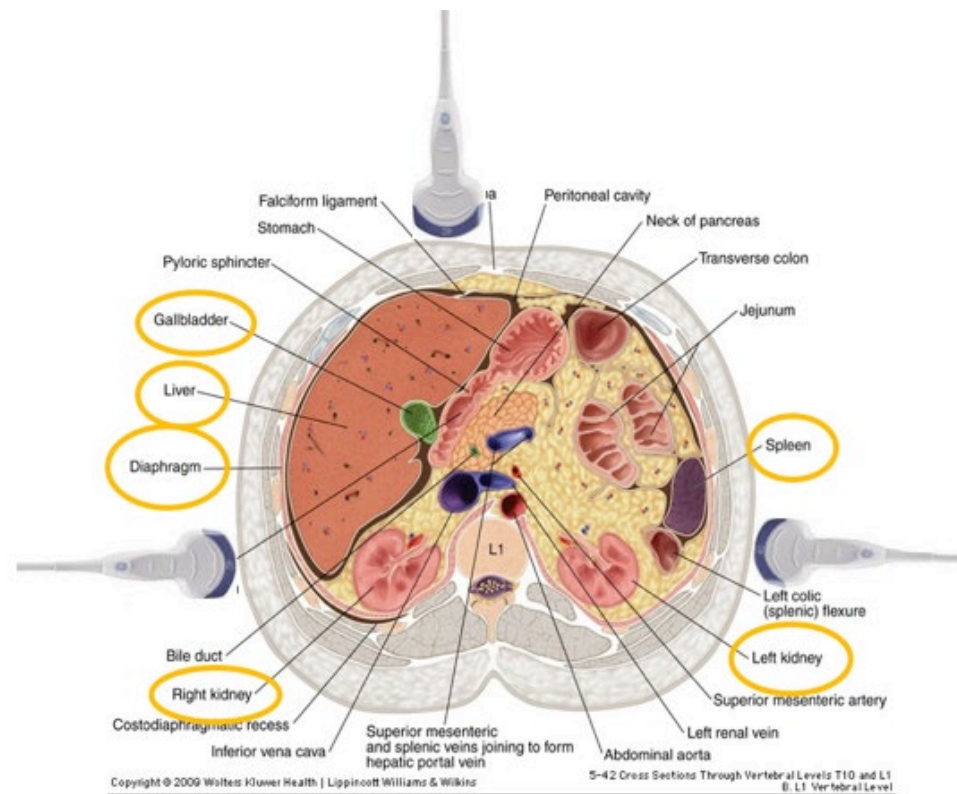
- Correlate anatomic structures identified during live-dissection with findings on ultrasound
- Demonstrate the ability to describe normal ultrasound anatomy in the abdomen
- Select the appropriate transducer and optimizing image capture by adjusting function keys

## ***HANDS-ON OBJECTIVES***

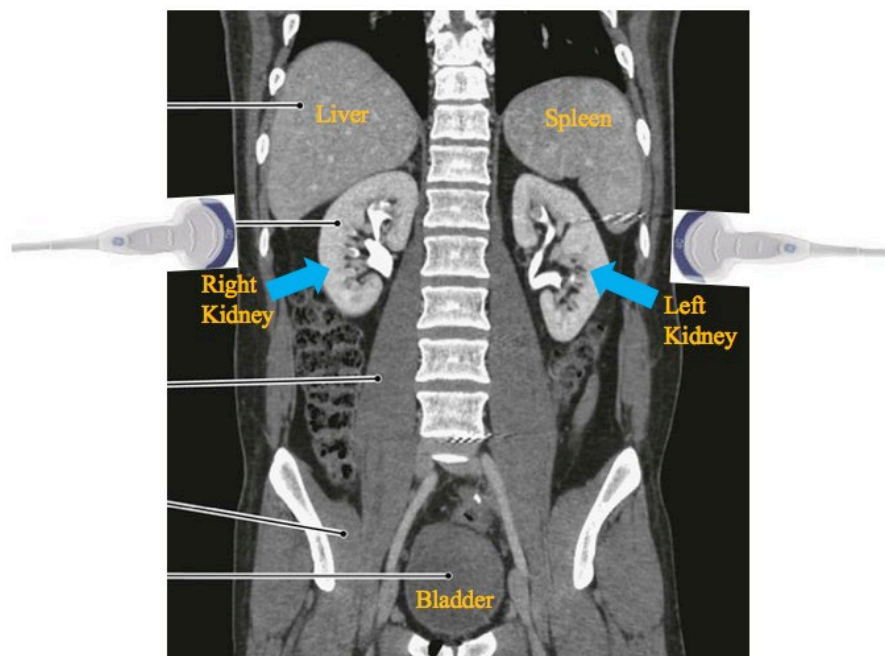
- Identify abdominal structures
  - ✓ Liver
  - ✓ Diaphragm
  - ✓ Hepatic Veins
  - ✓ Spleen
  - ✓ Right Kidney
  - ✓ Left Kidney

## ORIENTATION AND ANATOMY REVIEW

### *Transverse Section of Abdomen (Level of L1)*



### *Coronal Section, Abdominal CT*



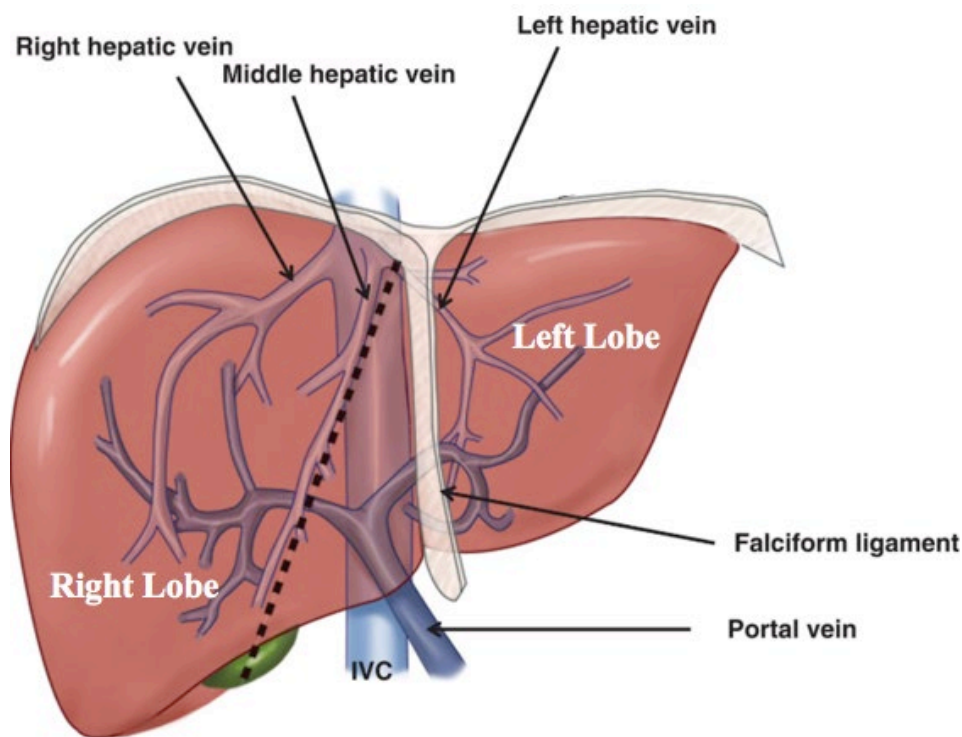
Structure of the Human Body  
Click here to enter a date.

Amy Kule, MD (akule@lumc.edu)  
Student Version

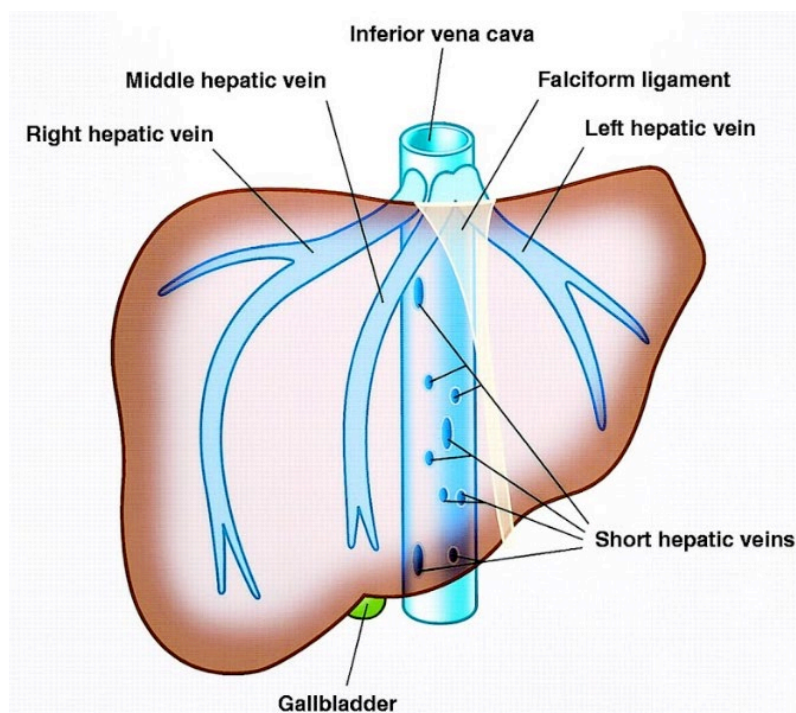
Credit: [www.radiologykey.com](http://www.radiologykey.com)

## LIVER AND SPLEEN ULTRASOUND

### *Liver Anatomy*



Credit: <https://www.cambridge.org/core/books/atlas-of-surgical-techniques-in-trauma>



Credit: <https://sites.google.com/site/odettesonographyportfolio/>

## ***Liver Ultrasound Scanning***

### Probe Selection:

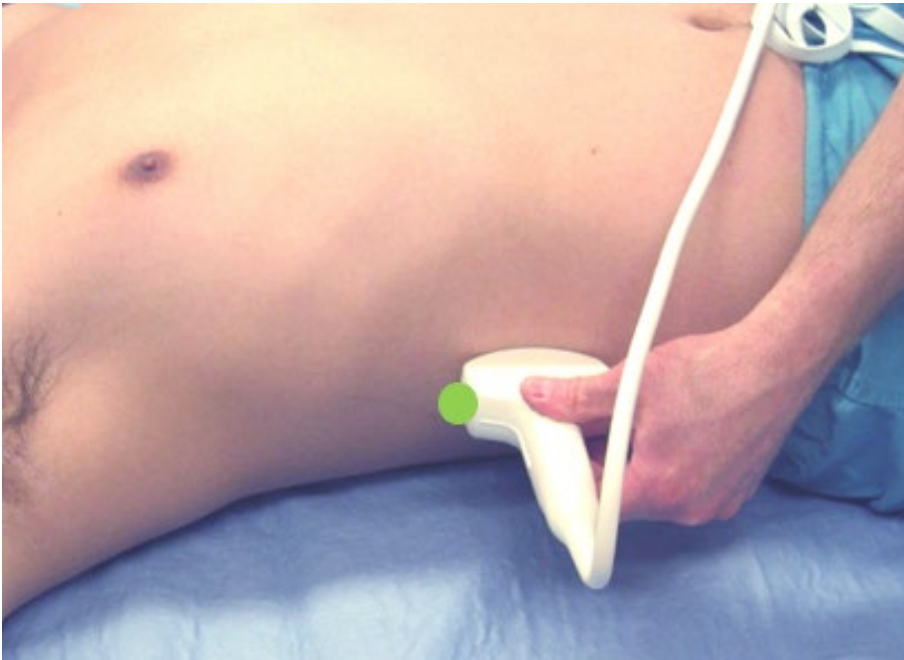
- Curvilinear
- Phased array

### Patient Positioning and Preparation:

- Supine
- Knees comfortably bent with right arm raised above the head
- Ideally, patient should be fasting before exam (to reduce bowel gas)

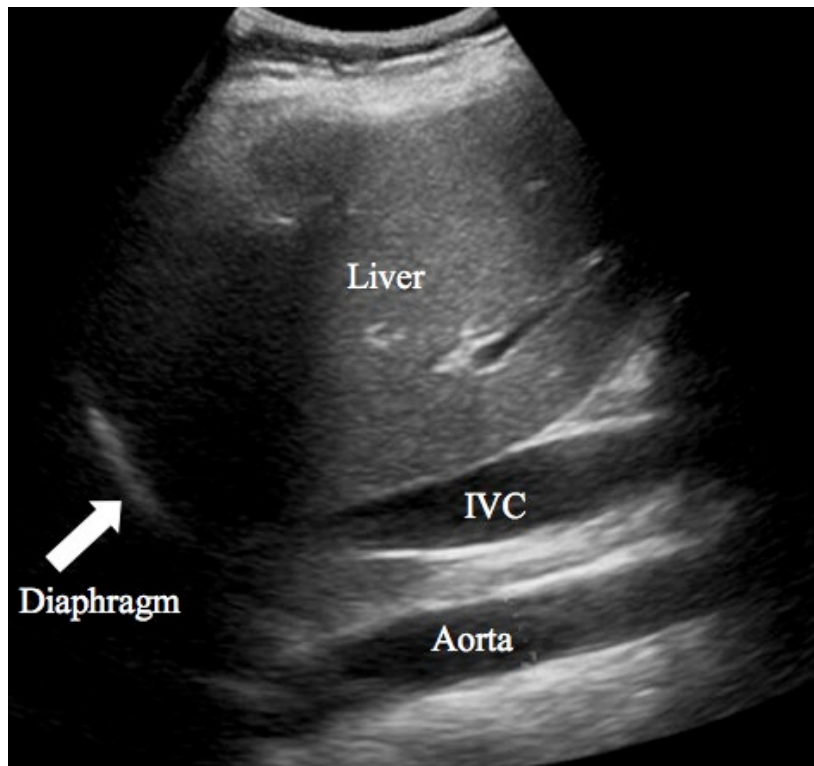
### 1. Technique for Mid-Axillary Coronal Scan Plane

- Place probe along the right mid-axillary line at the level of the xiphoid process (or at about the 9<sup>th</sup> or 10<sup>th</sup> intercostal space)
- Probe marker will be aimed towards the patient's head

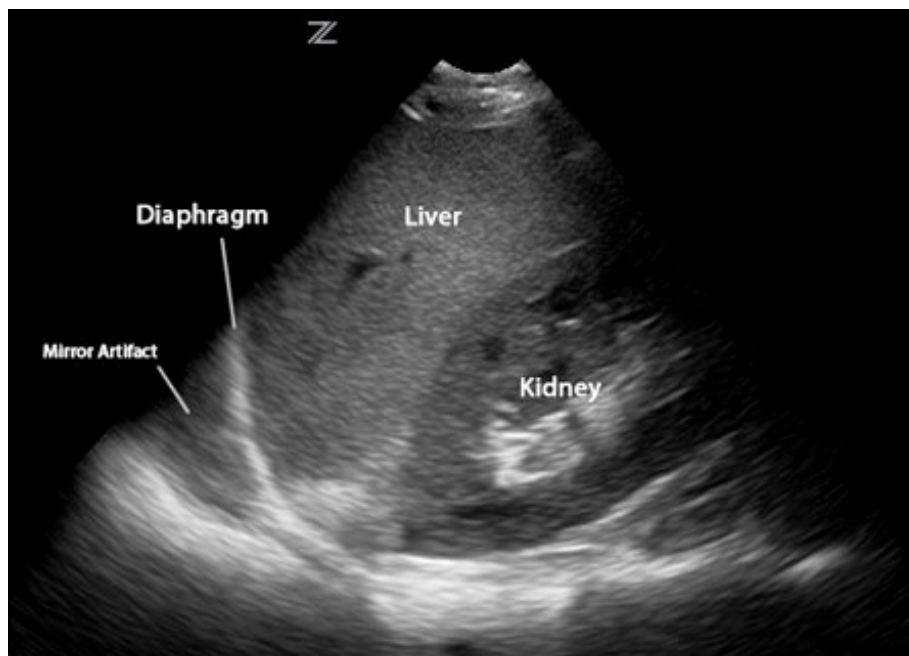


- The normal liver will have a homogenous, echogenic appearance with the portal and hepatic vessels scattered throughout
- Superior to the liver lies the hyperechoic diaphragm (towards the left screen). As the patient inhales and exhales, you can observe the corresponding movement of the diaphragm and mobility of the liver moving during the respiratory cycle

- The IVC may become apparent by fanning or sweeping the transducer more anteriorly



- The right kidney can be visualized by fanning or sweeping the probe more posteriorly





2. Technique for Subcostal Scan Plane:

- Probe is placed beneath the ribs in transverse orientation, angled cephalad (towards the head)
- Instruct patient to take a deep breath to better visualize the superior border of the liver and the hyperechoic diaphragm
- Fan and sweep the transducer along the subcostal margin to fully visualize the liver and its margins
- A fair amount pressure may be required to visualize the underlying structures
- If the structures are obscured by bowel gas, attempt to scan through the lower ribs at the level of the xiphoid process. Probe will remain in transverse orientation, but remain perpendicular to the skin

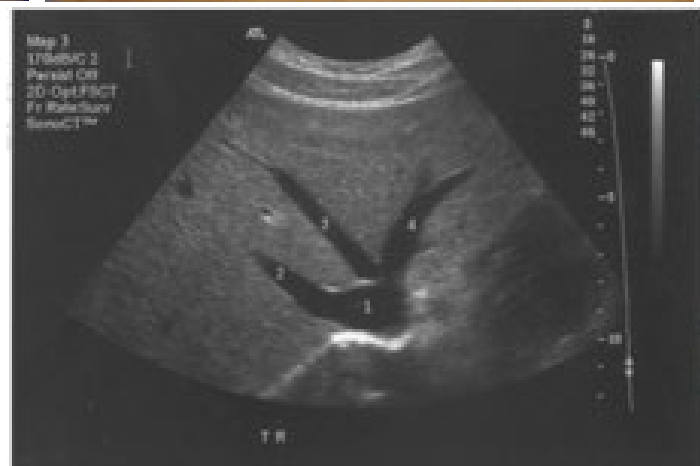
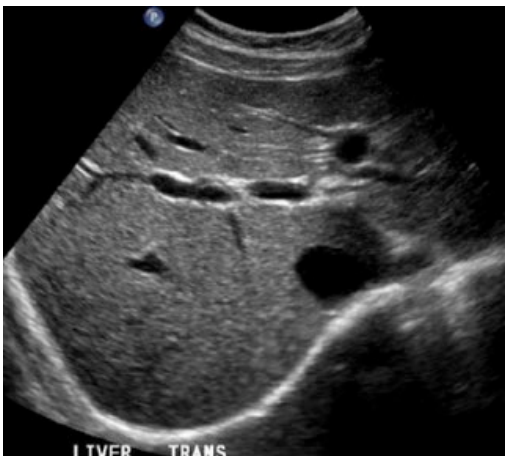
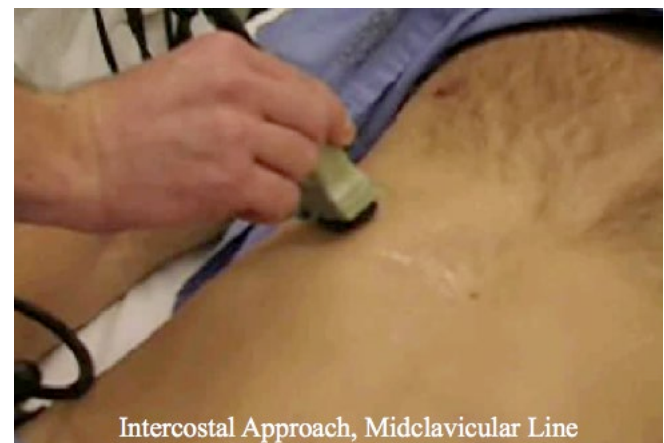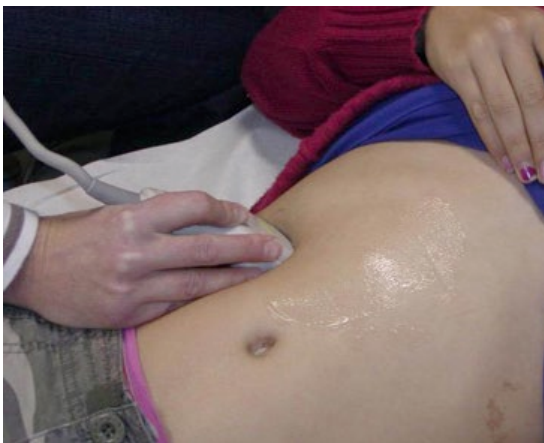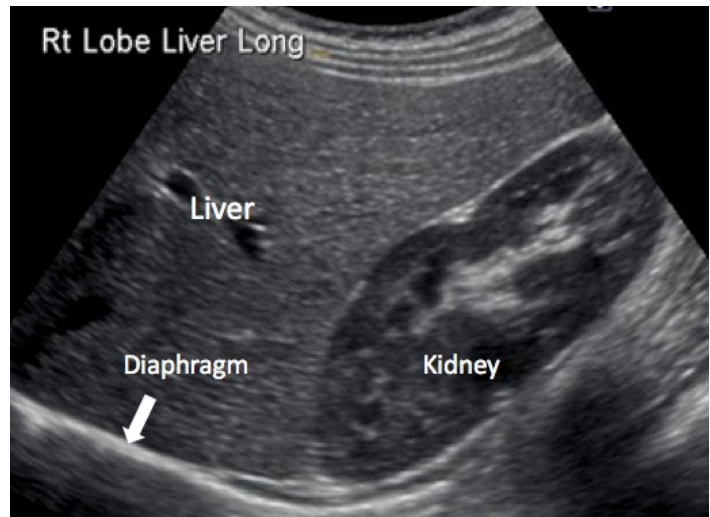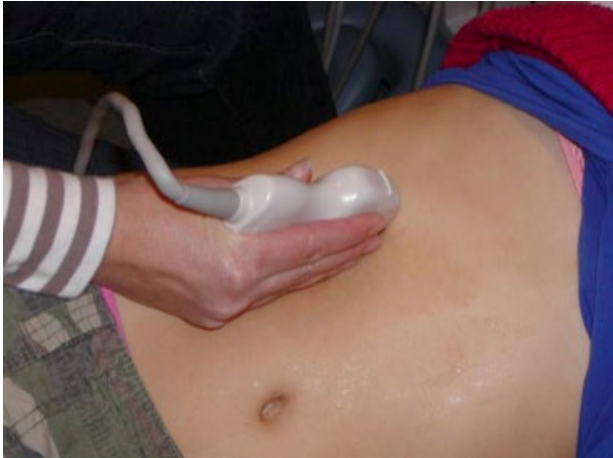Figure 2-7 Hepatic veins. A transverse sonogram showing right (2), middle (3), and left (4) hepatic veins draining into the inferior vena cava (1).

3. Technique for Longitudinal Scan Plane:

- Rotate the probe 90 degree and place in longitudinal orientation at the midclavicular line
- Sweep the probe laterally to medially to obtain a view of the diaphragm, liver and right kidney

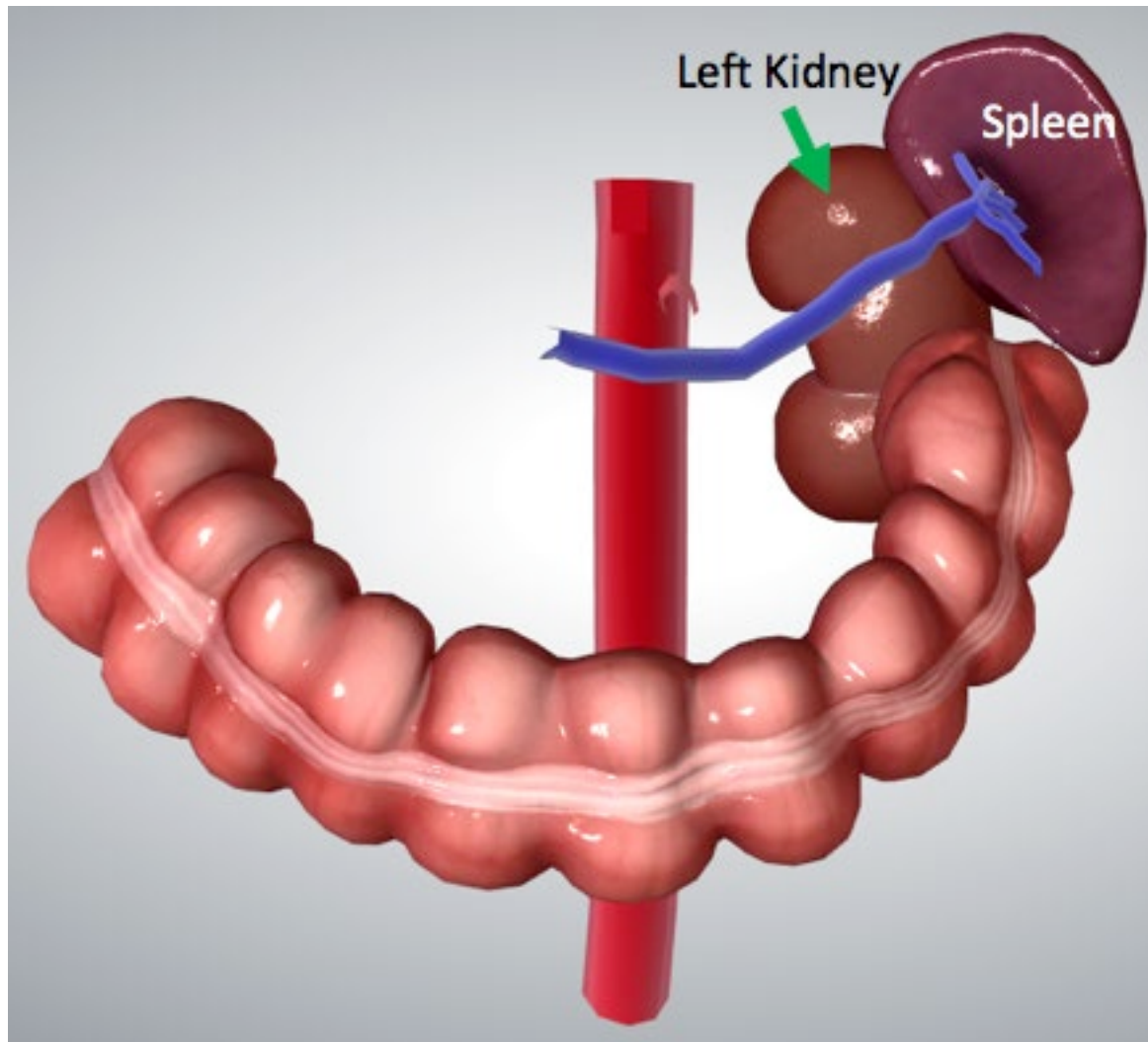


Structures to Identify:

- ✓ Liver
- ✓ Diaphragm
- ✓ Hepatic Veins
- ✓ Right Kidney



## ***Spleen Anatomy***



## ***Spleen Ultrasound Scanning***

### Probe Selection:

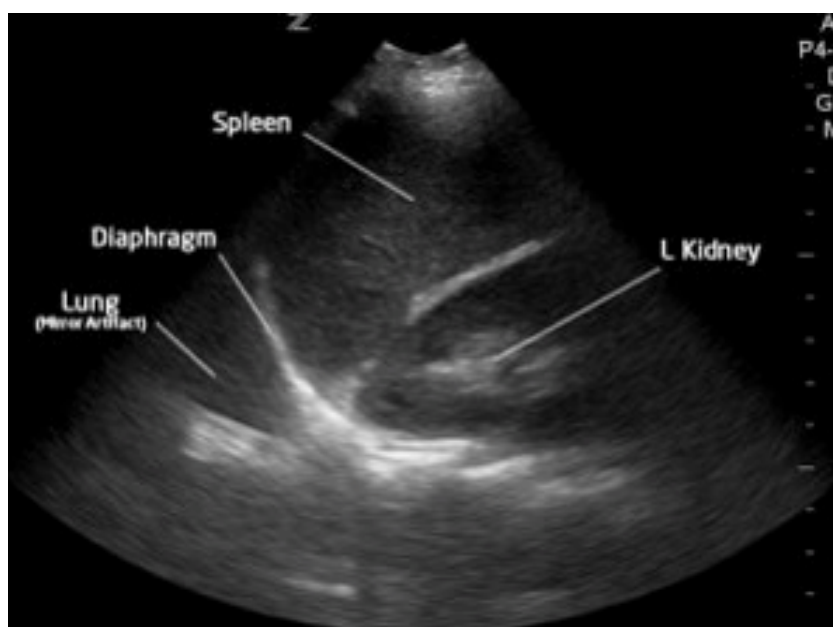
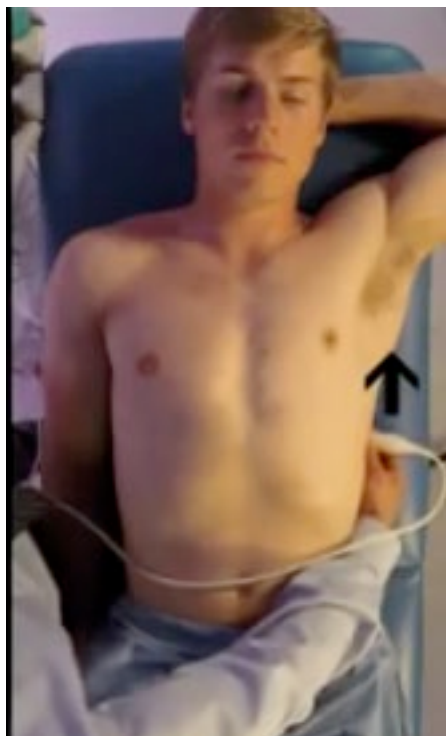- Curvilinear
- Phased array

### Patient Positioning and Preparation:

- Supine
- Knees comfortably bent with left arm raised above the head
- Ideally, patient should be fasting before exam (to reduce bowel gas)

### 1. Technique for Mid-Axillary Coronal Scan Plane

- Place probe along the left posterior-axillary line at the level of the xiphoid process (or at about the 8<sup>th</sup> intercostal space). Key probe positioning is “knuckles to the bed” given the more posterior location of these structures.
- Probe marker will be aimed towards the patient’s head, but can be oriented slightly oblique to run in the direction of the ribs to avoid rib shadow
- Poor visualization may occur due to overlying bowel gas, the lower lungs, or rib shadow.
  - Tips: Slowly roll the patient to the right lateral decubitus position. Try to improve visualization by scanning on deep inspiration, expiration, having the patient sit upright



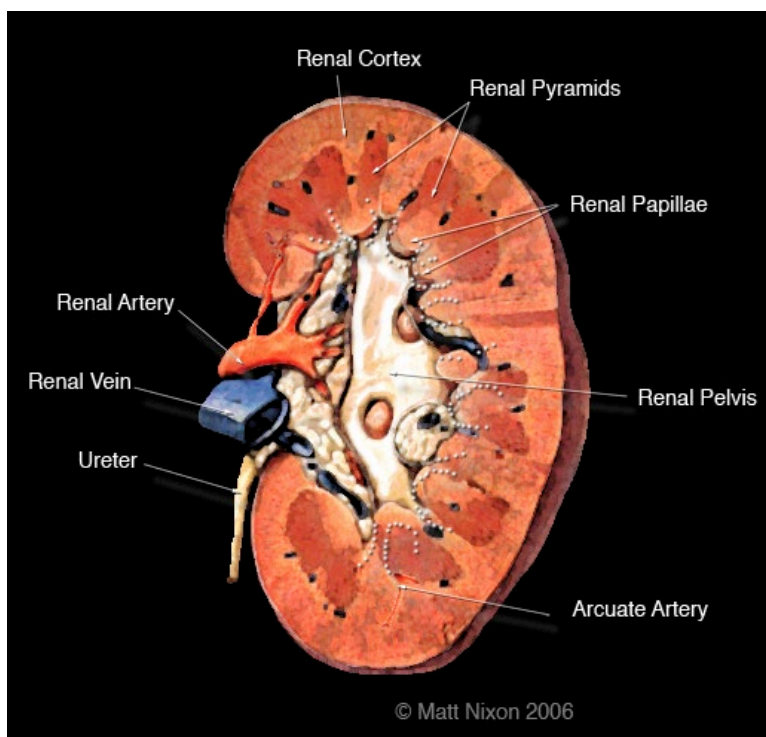
- The normal spleen will have a homogenous, “inverted comma” appearance
- Superior to the spleen (left side of the screen), the hyperechoic diaphragm can be visualized. Similar when scanning the liver, the diaphragm and spleen are mobile during respiration
- The left kidney can also be visualized in this view

### Structures to Identify:

- ✓ Spleen
- ✓ Diaphragm
- ✓ Left Kidney

## RENAL ULTRASOUND

### *Renal Anatomy*



### *Renal Ultrasound Scanning*

#### Probe Selection:

- Curvilinear
- Phased array

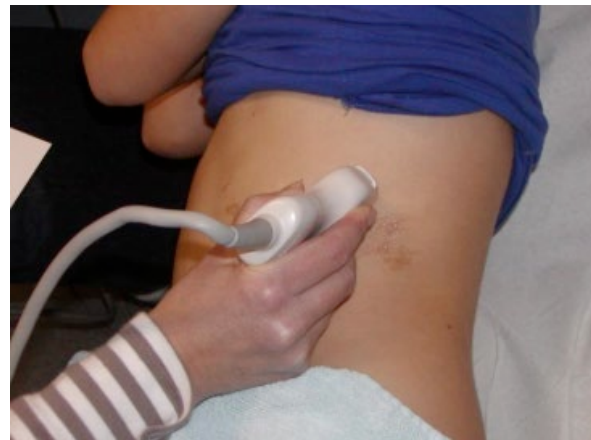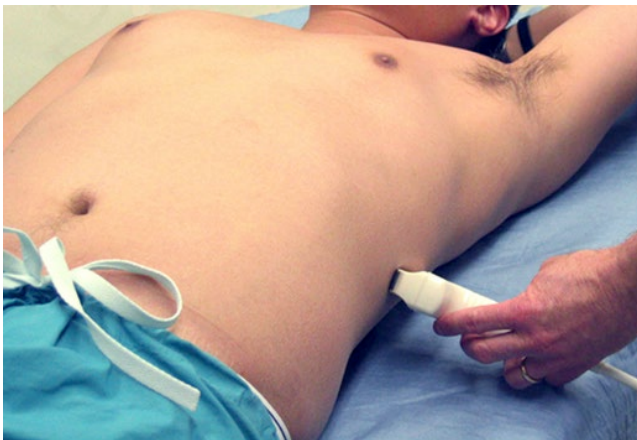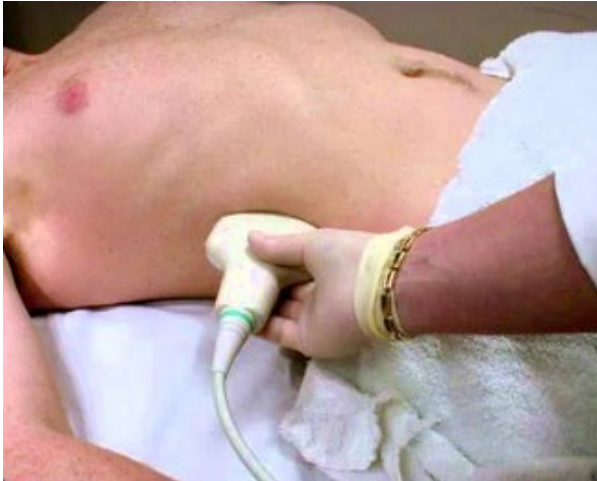#### Patient Positioning and Preparation:

- Supine
- Consider lateral decubitus for a posterior approach

#### 1. Renal Scanning Technique:

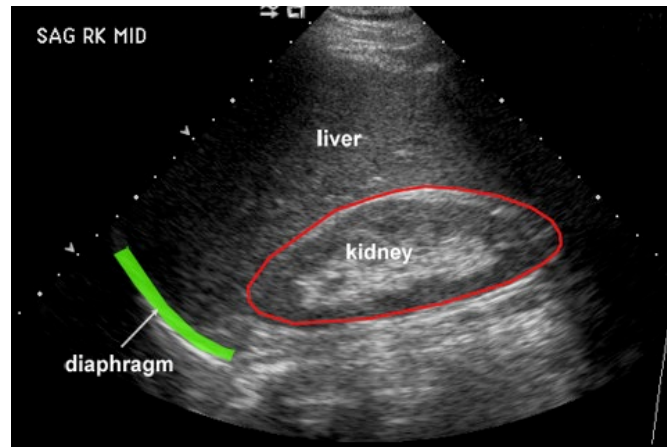
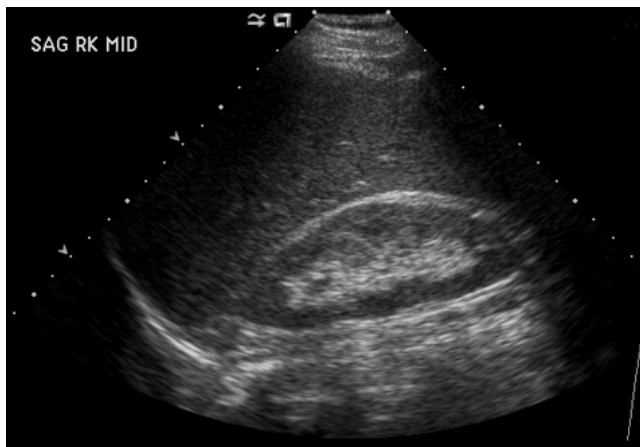- To obtain views of the right kidney, place the probe in the coronal orientation in the right lower intercostal space in the mid-axillary line. The right kidney lies below the liver in the retroperitoneal space.
- To view the left kidney, place the probe again in a coronal orientation, but in the left lower intercostal space in the posterior axillary line. The left kidney lies below the spleen.
- Compared to the right, the left kidney is positioned more cephalad (about 2-8 cm) and more posterior. Therefore, the ultrasound probe may be resting almost on the level of the bed to obtain views of the left kidney.

- Rock and fan the probe to scan through the entire kidney. Rotate the probe 90 degrees to obtain a transverse view of the kidneys.
- Consider angling the probe slightly oblique (probe marker towards the bed) to avoid rib shadow artifact.
- Instructing the patient to take and hold a deep breath can bring the kidney caudally into view.

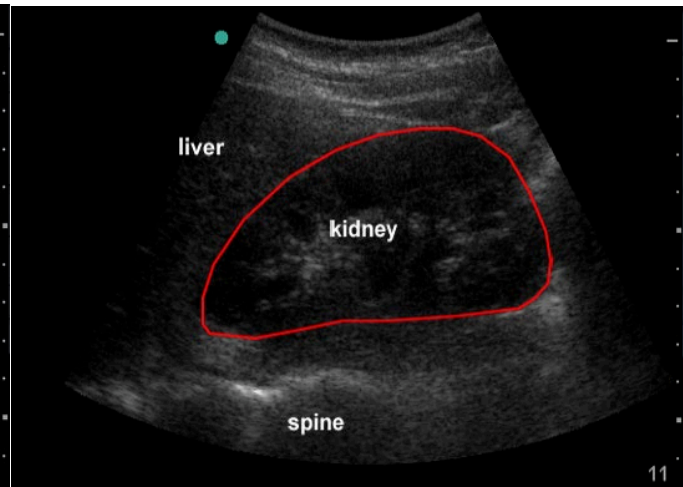
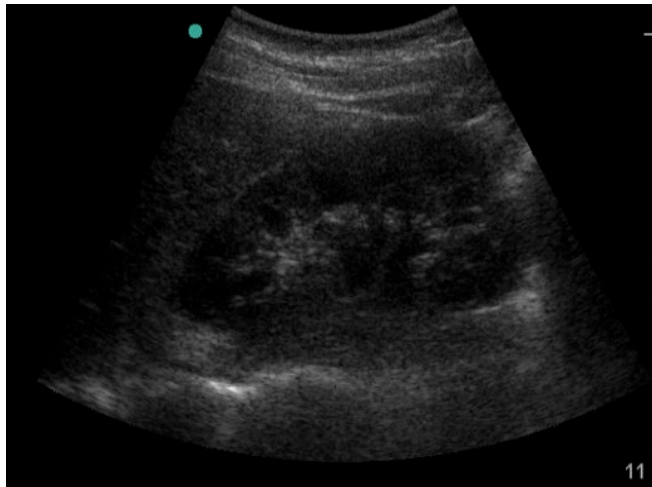


- On longitudinal view, the kidney appears football shaped, whereas on transverse view it appears C-shaped.
- Gerota's fascia and perinephric fat surrounds the kidney, which is seen as hyperechoic on ultrasound
- The periphery is made up of the renal cortex and pyramids, which appear grainy and hypoechoic compared to the renal capsule
- The central area (renal sinus) consists of the calyces, renal pelvis and renal sinus fat. This will appear hyperechoic on ultrasound

***Sagittal (longitudinal) view of the right kidney***



***Transverse view of the right kidney***



**Structures to Identify:**

- ✓ Right Kidney
- ✓ Left Kidney

---

**References:**

1. <https://www.acep.org/sonoguide>
2. <http://lluultrasound.org/home/ebook/original-abdominal/>
3. <http://www.ultrasoundpaedia.com/normal-liver2/#protocol>
4. [https://wn.com/kidneys\\_ureters\\_and\\_bladder\\_ultrasound\\_scan](https://wn.com/kidneys_ureters_and_bladder_ultrasound_scan)
5. [http://samples.jbpub.com/9780763765583/65583\\_CH02\\_5378.pdf](http://samples.jbpub.com/9780763765583/65583_CH02_5378.pdf)
6. <https://human.biodigital.com/index.html>