

# Musculoskeletal Ultrasound (Shoulder)

## Workshop:

**Location:** SSOM, L71

## Watch:

- **iTunes “MSK Anatomical Ultrasound” Video: (watch to 25:20)**  
<https://itunes.apple.com/us/podcast/ms1-ultrasound-in-meded/id429668500?mt=2>
- **US of the Bicep Tendon (1:26)**  
[https://www.youtube.com/watch?time\\_continue=24&v=Lu8vcQQS0VY](https://www.youtube.com/watch?time_continue=24&v=Lu8vcQQS0VY)
- **US of the Subscapularis Tendon (1:28)**  
<https://www.youtube.com/watch?v=81XRvOWGekM>
- **US of the Infraspinatus Tendon (1:06)**  
<https://m.youtube.com/watch?v=uWR9Of93A58>
- **US of the Acromioclavicular Joint (1:02)**  
[https://www.youtube.com/watch?time\\_continue=15&v=BoSkei5FZhk](https://www.youtube.com/watch?time_continue=15&v=BoSkei5FZhk)

## ***LEARNING OBJECTIVES***

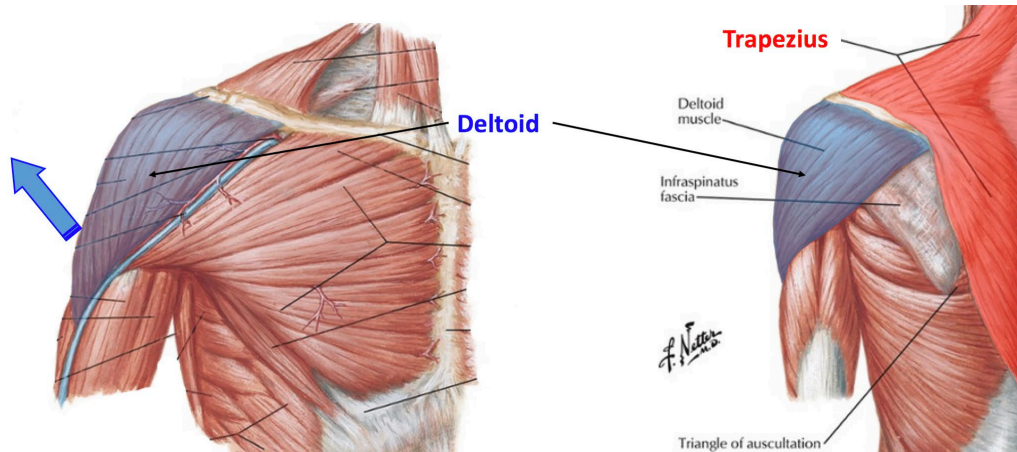
- Correlate anatomic structures identified during live-dissection with findings on ultrasound
- Demonstrate the ability to describe and identify normal ultrasound anatomy in the shoulder
- Describe the difference in appearance between soft tissue, bone, muscle and tendon on ultrasound
- Select the appropriate transducer and optimizing image capture by adjusting function keys

## ***HANDS-ON OBJECTIVES***

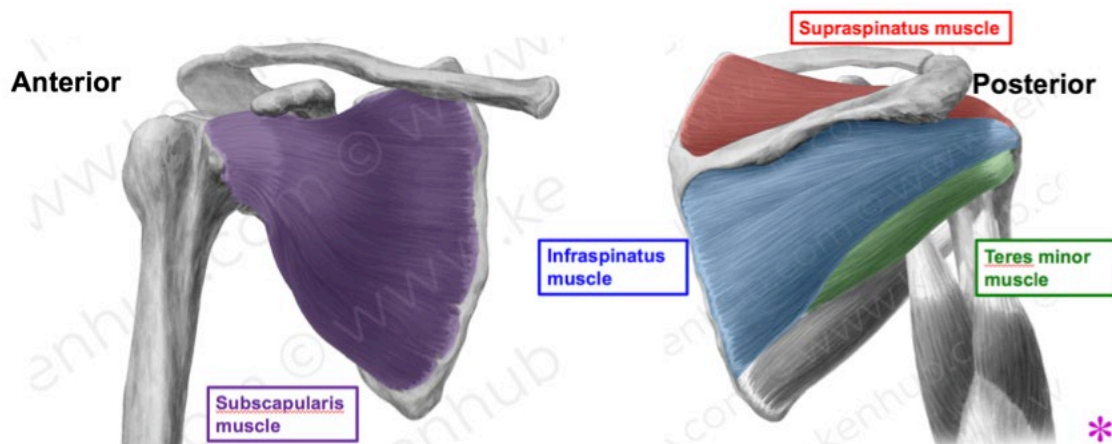- Identify structures in the Shoulder
  - Anterior
    - Deltoid muscle (anterior portion)
    - Greater tuberosity
    - Lesser tuberosity
    - Intertubercular groove
    - Long head of the bicep brachii tendon
    - Subscapularis tendon and muscle
  - Posterior
    - Deltoid muscle (posterior portion)
    - Infraspinatus tendon and muscle
    - Humeral head
    - Glenoid
  - Superior
    - Clavicle (Lateral/distal aspect)
    - Acromion
    - Acromioclavicular (AC) joint

## SHOULDER ULTRASOUND

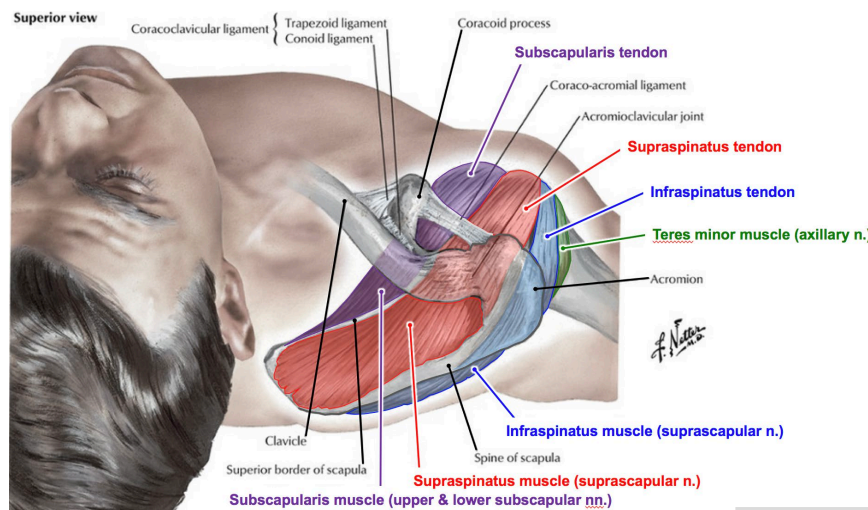
### *Gross Anatomy*



Credit: SHB Shoulder and Pectoral Region Ppt, Slide 12



Credit: SHB Shoulder and Pectoral Region Ppt, Slide 13



Credit: SHB Shoulder and Pectoral Region Ppt, Slide 13

## ***Ultrasound Anatomy***

### Probe Selection:

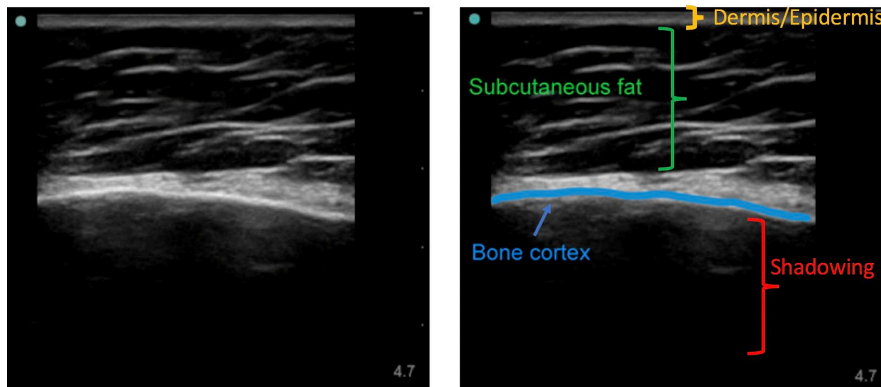
- *Linear* – as a higher frequency probe, the linear probe offers higher resolution of the underlying structures. However, depth is compromised, but is appropriate for use when scanning soft tissue and joints, as these structures are relatively close to the surface.
- *Curvilinear* – as a lower frequency probe, the curvilinear probe offers greater depth in the event that deeper structures are unable to be fully visualized with the linear probe. However, note that resolution may be compromised. It is important to decrease the depth when assessing shallower structures.

### Knobology:

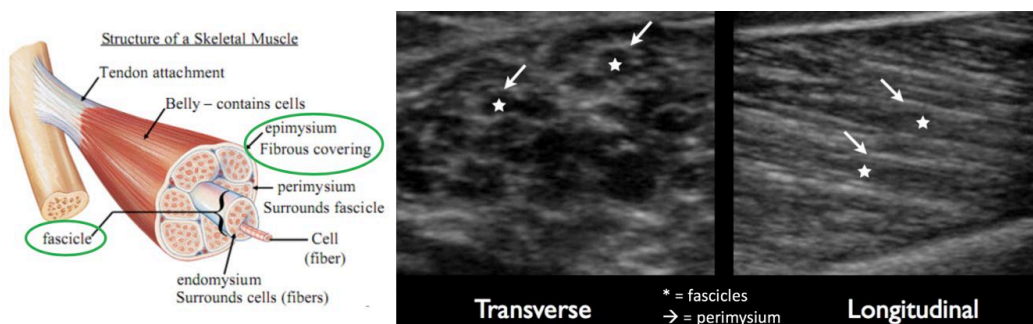
- *Exam type* – set the exam type to the “MSK” or “superficial” setting.
- *Depth* – adjust the initial depth appropriately to allow structures of interest to be visualized.

### Sonographic Anatomy:

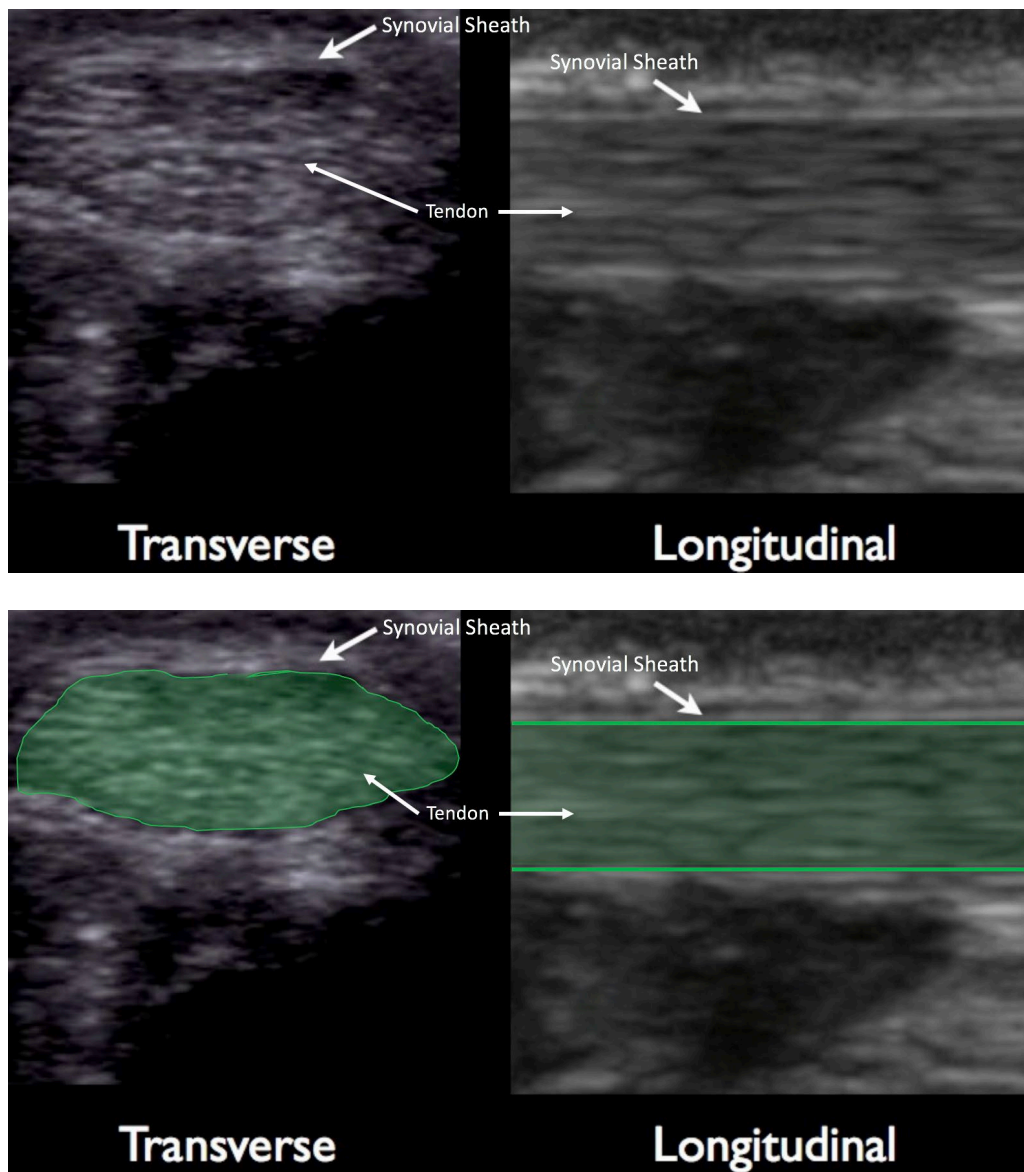
- *Epidermis and dermis* – as this is the first layer that has contact with the ultrasound probe, this will appear at the top of the screen. The epidermis and dermis layers are seen as one solid, hyperechoic line.
- *Subcutaneous fat* – appears relatively hypoechoic with thin septations of connective tissue. The thickness of this layer depends on the body habitus of the patient.
- *Bone* – the surface appears bright (hyperechoic) with no visible structures beneath. This is due to the hard, calcified cortex reflecting nearly all ultrasound waves back to the transducer.



- *Muscle* – the appearance depends whether the muscle is being scanned longitudinally or transversely, as the fascicles within the muscle belly are arranged longitudinally. In the longitudinal view, it appears as irregular lines. When viewed transversely, muscle appears dotted or form short lines.



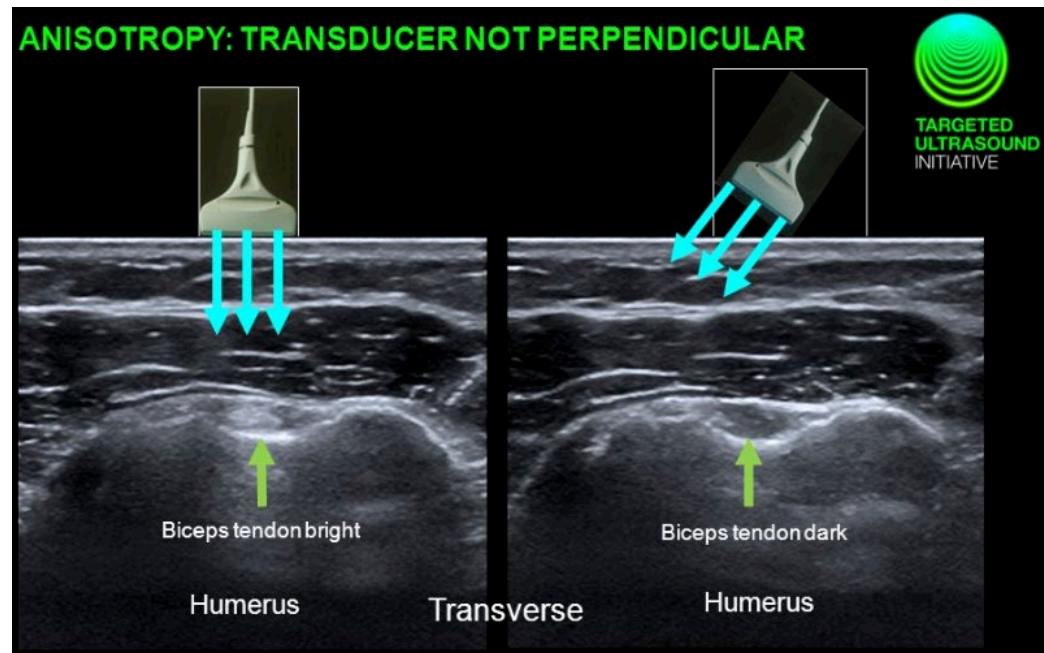
- *Tendon* – appears on ultrasound similar to muscle as the collagen fibrils that make up a tendon is also arranged longitudinally. However, contrary to muscle, the hyperechoic lines appear more uniform and brush-like in longitudinal plane, and as hyperechoic dots in transverse plane. The synovial sheath surrounds the tendon, which may appear as a hyperechoic line.



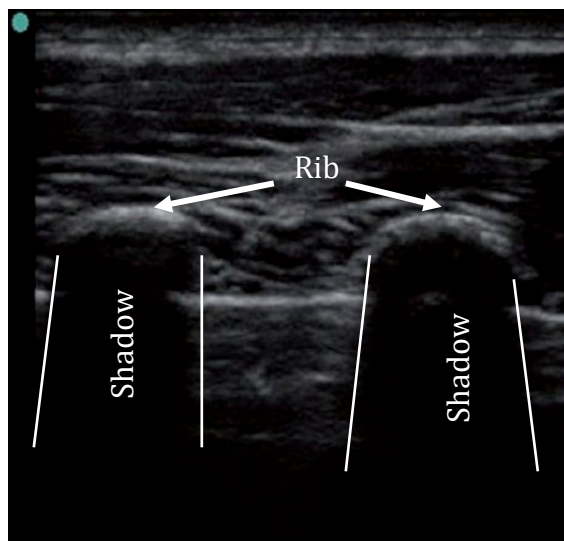
Additional Ultrasound Concepts:

- *Anisotropy*: artifact seen in musculoskeletal ultrasound (commonly tendons, ligaments, but occurs in muscles and nerves to a lesser extent). Occurs when the ultrasound beam encounters a structure at a non-perpendicular angle. Results in loss of echogenicity of the structure (appears more hypoechoic and makes visualization difficult).





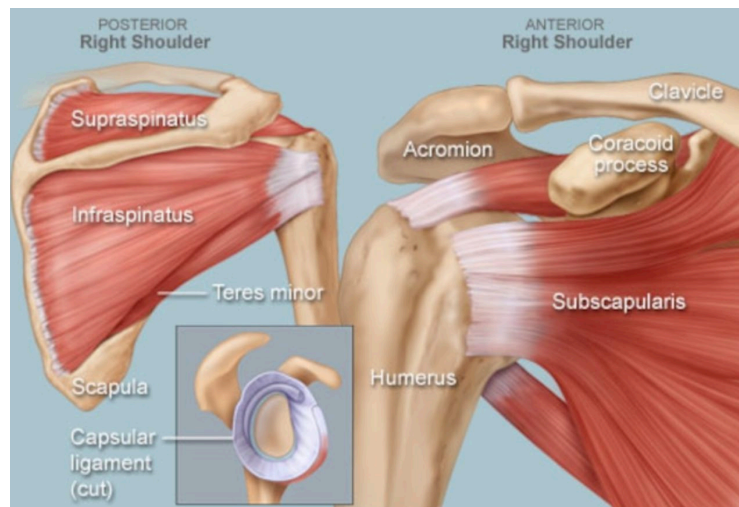
- *Posterior Acoustic Shadowing*: blocking of ultrasound beams when ultrasounding certain denser structures (i.e. bone) resulting in the near complete reflection of ultrasound waves returning to the transducer. The result is the appearance of shadowing behind the structure.



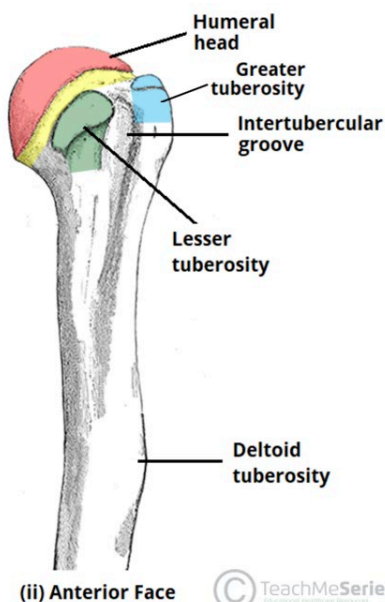
## **Anterior Shoulder/Proximal Humerus**

### **1. Patient Positioning and Examination with Palpation:**

- The patient is to be seated upright on the side of a bed or chair with the arm adducted, elbow bent and forearm supinated (palm up) on the thigh.
- Visualize the surface anatomy of the shoulder, the bony contours of the clavicle and acromion, and the outline of the bicep, deltoid, and trapezius muscles.
- Palpate the proximal anterior humerus and attempt to palpate a divot between the greater tuberosity (through the deltoid muscle) and lesser tuberosity. This divot is the intertubercular groove (or bicipital groove), which contains the long head of the biceps brachii tendon.



Credit: [www.webmd.com](http://www.webmd.com)

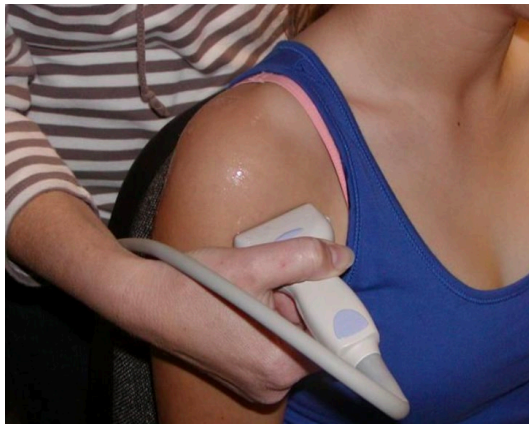



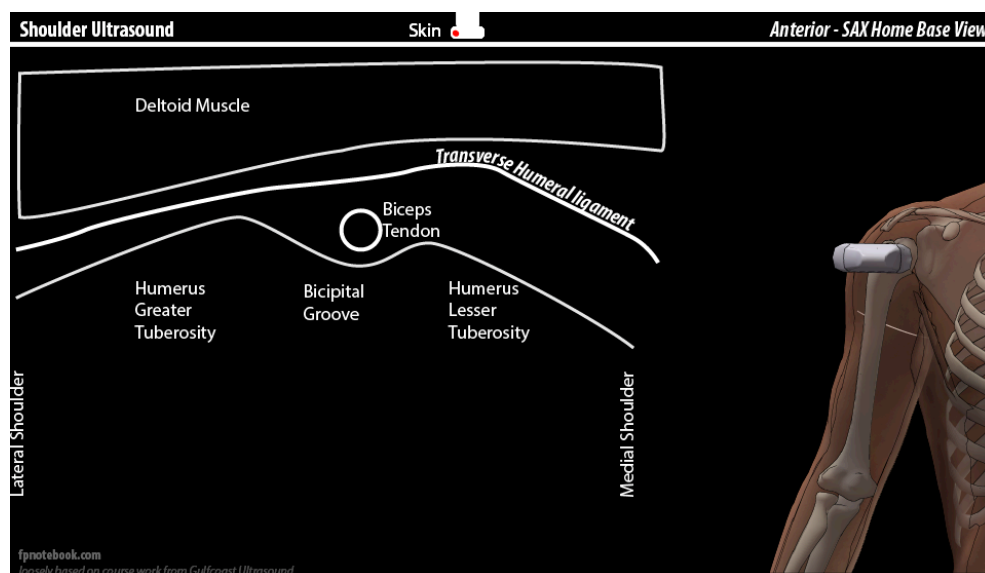
## 2. Ultrasound Technique:

### ➤ *Transverse plane*

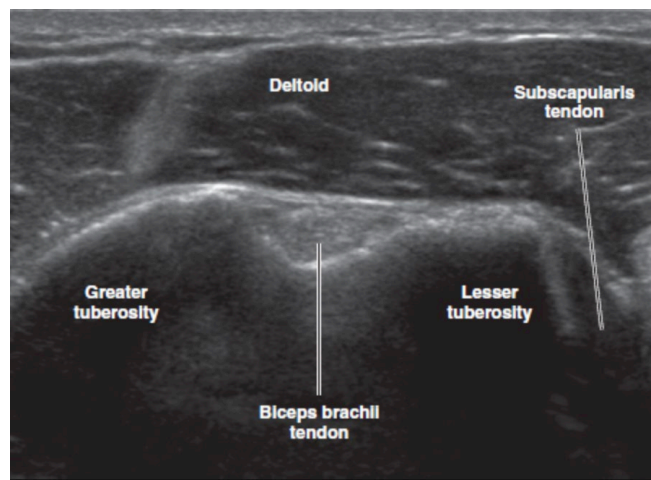
- Place the linear probe in transverse orientation to the anterior shoulder overlying the proximal humerus. The probe marker will be directed towards the patient's right side.



Transverse Biceps tendon scan plane

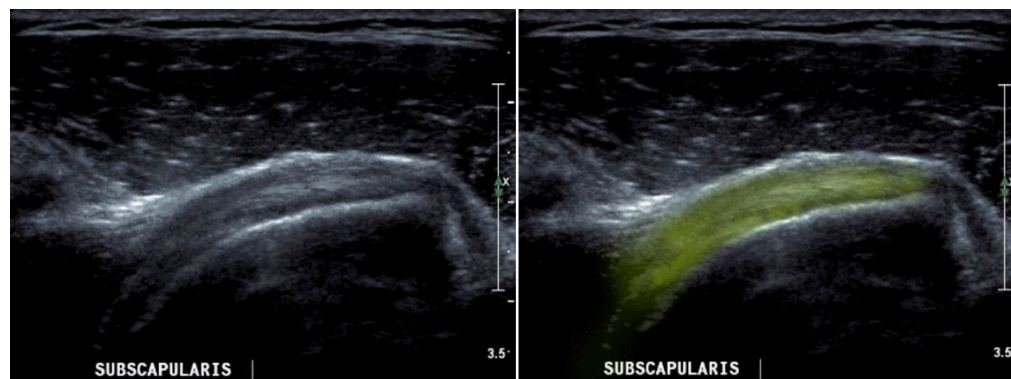
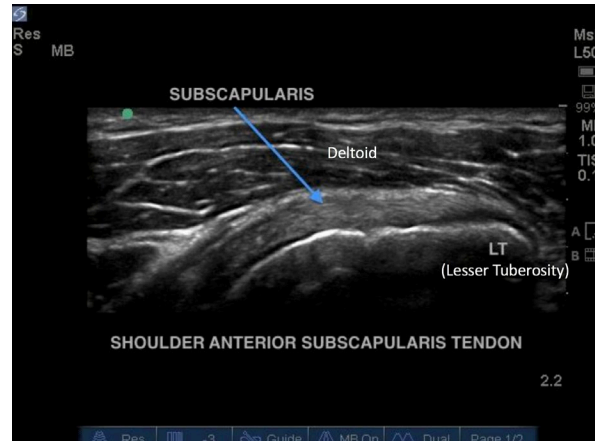


- Identify the bony landmarks of the proximal humerus: the greater tuberosity, lesser tuberosity, and intertubercular (bicipital) groove.
- Overlying the humerus will be the deltoid muscle.
- Within the intertubercular (bicipital) groove will be the longhead of the biceps brachii tendon. Fan the transducer to demonstrate anisotropy of the tendons (the echogenicity of the tendon will change depending on the angle of the probe).

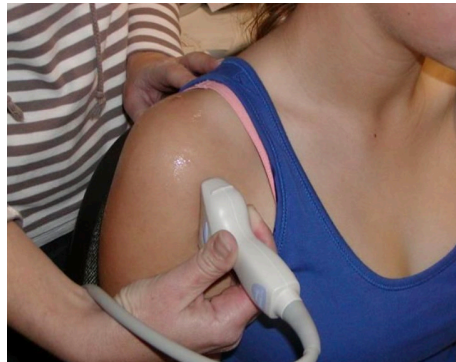

Credit: fadavispt.mhmedical.com

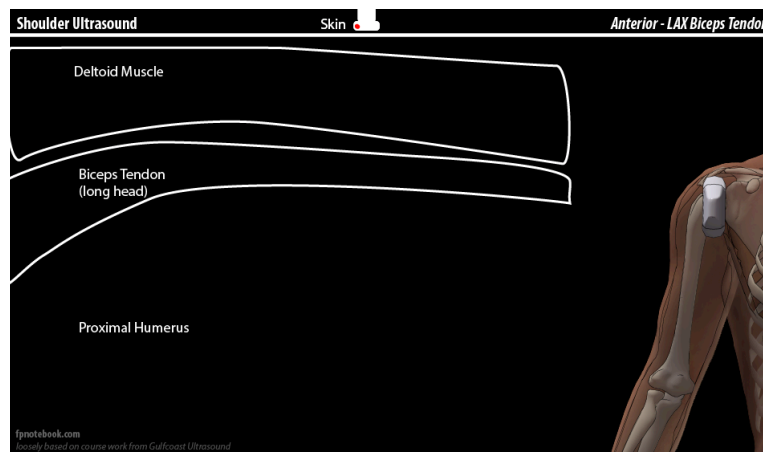
- While maintaining the probe position, passively externally and internally rotate the patient's forearm. Observe the subscapularis tendon and muscle come in and out of view across the lesser tuberosity. The insertion site of the subscapularis tendon is medial to the intertubercular (bicipital) groove at the lesser tuberosity.
- The subscapularis muscle assists with internal rotation and adduction of the shoulder.



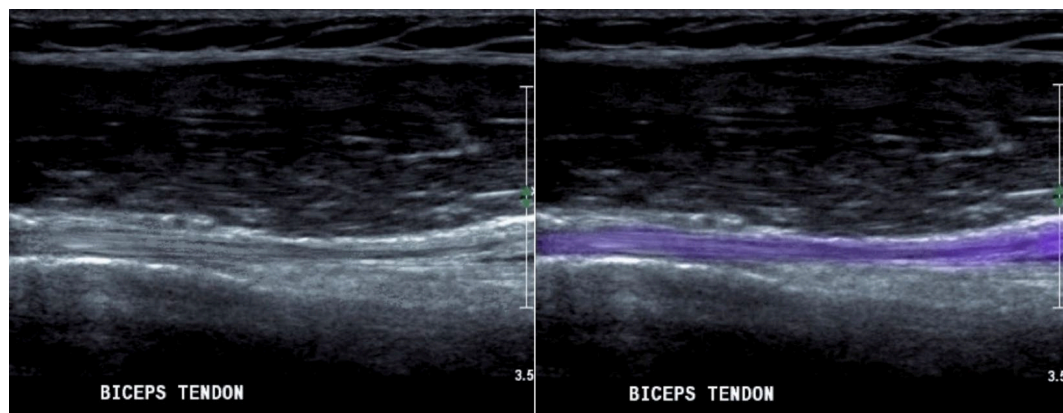
- *Longitudinal (sagittal) plane*
  - Rotate the the linear probe 90 degrees clockwise to orient the probe marker towards the patient's head.




Longitudinal Biceps tendon scan plane



- The bicep tendon will appear in longitudinal view. Take note of the difference in how the bicep tendon appears between the transverse and longitudinal views.



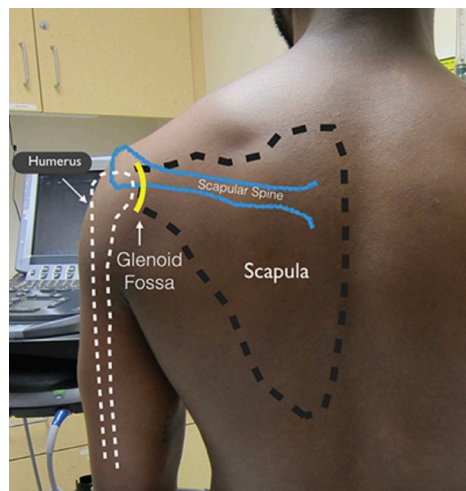
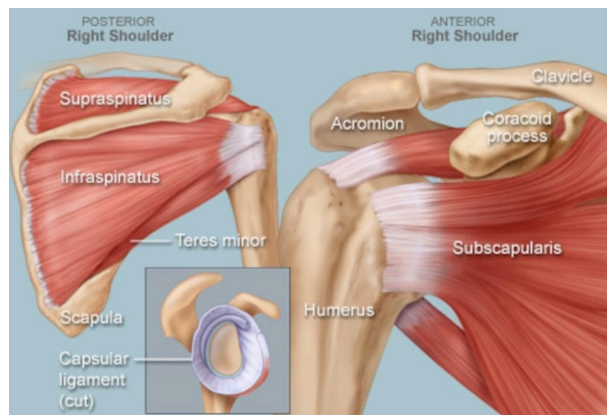
Structures to Identify:

- Deltoid muscle (anterior portion)
  - Greater tuberosity
  - Lesser tuberosity
  - Intertubercular (bicipital) groove
  - Long head of the bicep brachii tendon
  - Subscapularis tendon and muscle
- 
- A vertical curly bracket on the right side of the list groups the first four items: Deltoid muscle (anterior portion), Greater tuberosity, Lesser tuberosity, and Intertubercular (bicipital) groove.
- Proximal Humerus

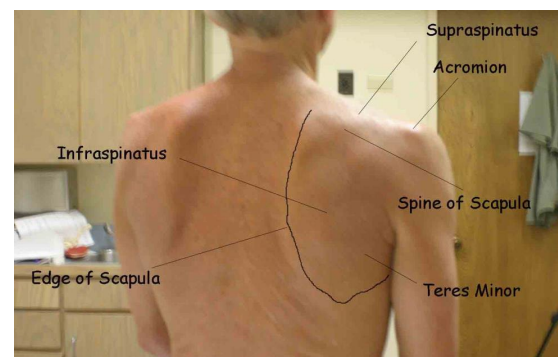
## **Posterior Shoulder/Proximal Humerus**

### **1. Patient Positioning and Examination with Palpation:**

- The patient is to be seated upright on the side of a bed or chair with the arm adducted with the hand resting on the contralateral shoulder.
- Visualize the surface anatomy of the shoulder, including the outline of the scapula, posterior and lateral aspects of the deltoid and trapezius muscles.
- Palpate the scapular spine. The scapular spine distinguishes the supraspinous fossa from the infraspinous fossa.
- The supraspinatus muscle sits within the supraspinous fossa and the infraspinatus muscle within the infraspinous fossa.



Credit: [www.acepnow.com](http://www.acepnow.com)



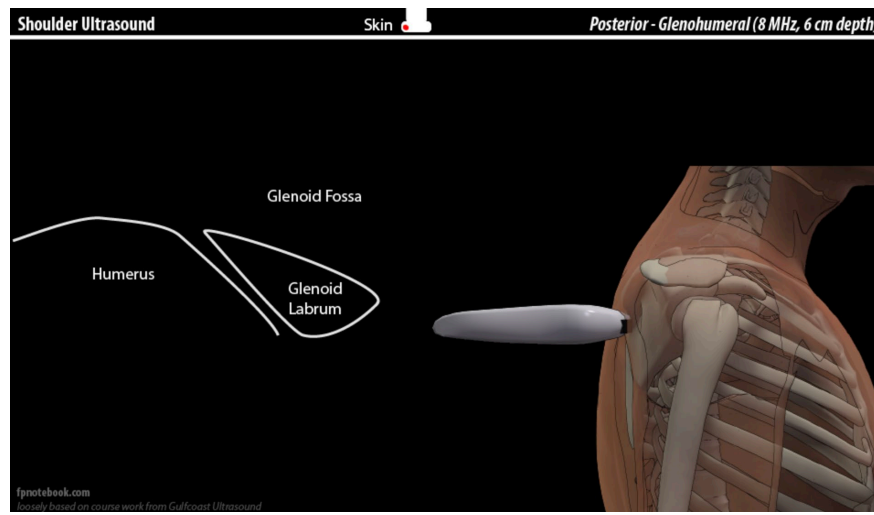
Credit: <http://hsc.ghs.org/wp-content/uploads/2015/04/0309-Masocol-Upper-Extremity-Joint-Exams.pdf>

### **2. Ultrasound Technique:**

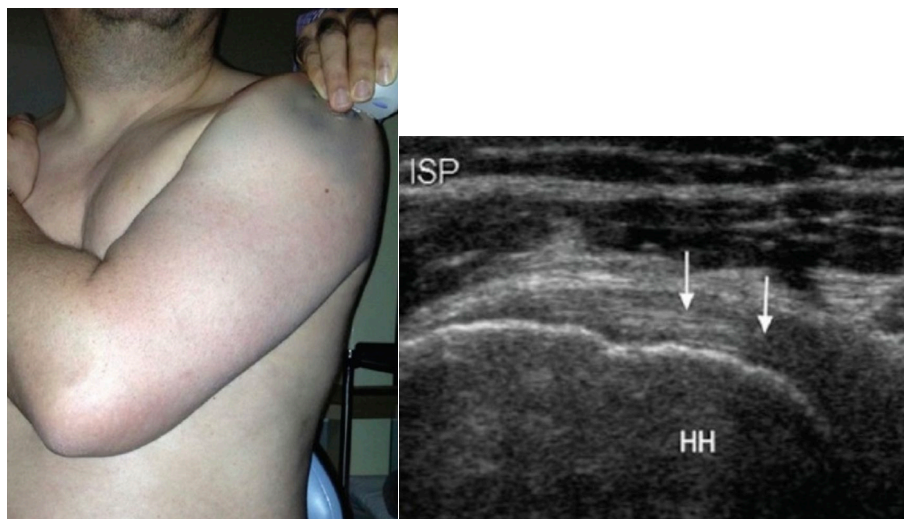


➤ *Transverse plane*

- Place the linear or curvilinear probe in transverse orientation at the posterior shoulder just inferior to the scapular spine. This will be the region of the infraspinous fossa. The probe marker will be directed towards the patient's right side. Hold the probe parallel to the ground.



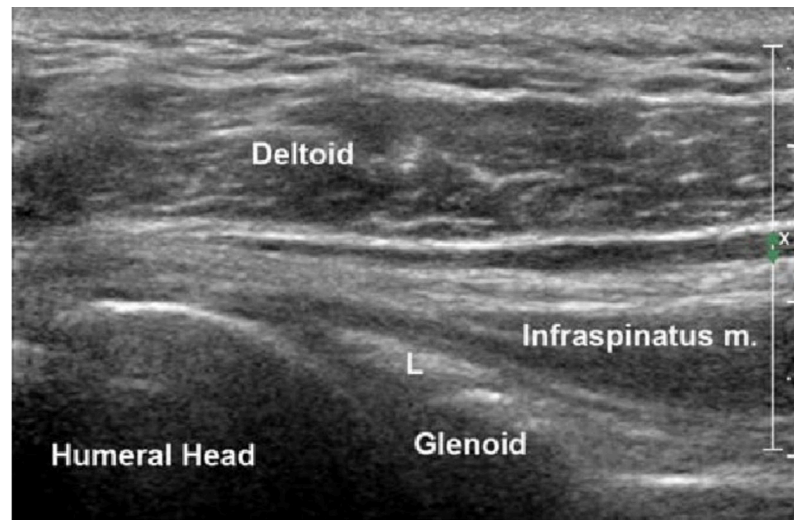
- Slide the probe laterally towards the proximal humeral head.
- Identify the bony landmarks of the glenohumeral joint comprised of the humeral head and glenoid. These will appear hyperechoic with posterior shadowing.
- The infraspinatus tendon will be seen in longitudinal view. Therefore, it appears homogenous as a collection of parallel lines and resembles a bird beak at its insertion at the greater tuberosity of the humerus.



Credit: Singh J. Shoulder ultrasound: What you need to know. Indian J Radiol Imaging. 2012 Oct-Dec; 22(4): 284-292.

- Provide gentle passive or active internal and external rotation of the patient's forearm while watching for dynamic movement of the shoulder structures.

Observe the infraspinatus tendon and muscle enter into and out of view over the humeral head.



Credit: Chen C, Lew H, Hsu C. Ultrasound-guided glenohumeral joint injection using the posterior approach. Am J Phys Med Rehabil. 2015 Dec; 94(12): e117-118.

Structures to Identify:

- Deltoid muscle (posterior portion)
- Infraspinatus tendon and muscle
- Humeral head
- Glenoid

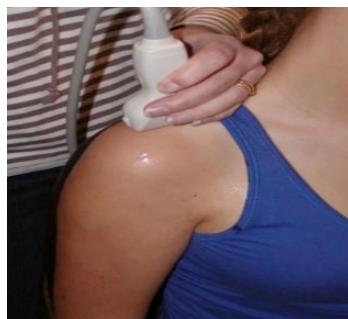## Acromioclavicular Joint and Tendon

### 1. Patient Positioning and Examination with Palpation:

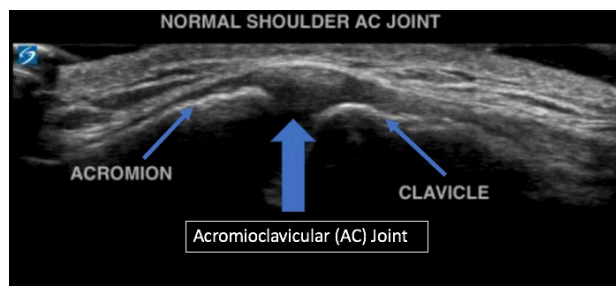
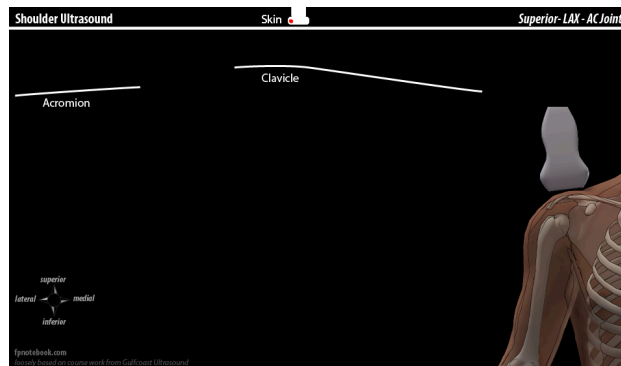
- The patient is to be seated upright on the side of a bed or chair with the arm adducted, elbow bent and forearm supinated (palm up) on the thigh.
- Palpate the clavicle from the sternoclavicular joint (medially) to the acromioclavicular joint (laterally). Continue laterally to palpate the acromion.

### 2. Ultrasound Technique:

- The probe will be placed in the coronal plane on the superior aspect of the shoulder. Another way to consider placement is long axis relative to the clavicle.
- With the probe marker directed to the patient's right side, the acromion will appear on the left side of the screen, while the distal (lateral) clavicle will appear on the right side of the screen. *\*Note this is only if scanning the right shoulder. It will appear on opposite sides of the screen if scanning the left shoulder.*
- The acromioclavicular joint can be identified as the space between the acromion and clavicle. To better appreciate this joint, ask the patient to reach across and touch the contralateral shoulder while maintaining the probe positioning. This may open up the AC joint space to make this space more visible.



ACJ scan plane



### Structures to Identify:

- Clavicle (Lateral/distal aspect)
- Acromion
- Acromioclavicular (AC) joint

**References:**

1. <https://pubs.rsna.org/doi/full/10.1148/radiol.11101082>
2. <https://www.acep.org/sonoguide/musculoskeletal.html>
3. <https://www.sonosite.com/>
4. <https://www.ultrasoundpaedia.com/normal-shoulder/>
5. <http://ultrasoundconnection.com/word-of-the-day-anisotropy/>