

Neck Ultrasound

Workshop:

Location: SSOM, L71

Watch:

- **Neck Ultrasound Scanning Protocol (4:00):**
<https://www.youtube.com/watch?v=zozD2x2Ll4Q>

LEARNING OBJECTIVES

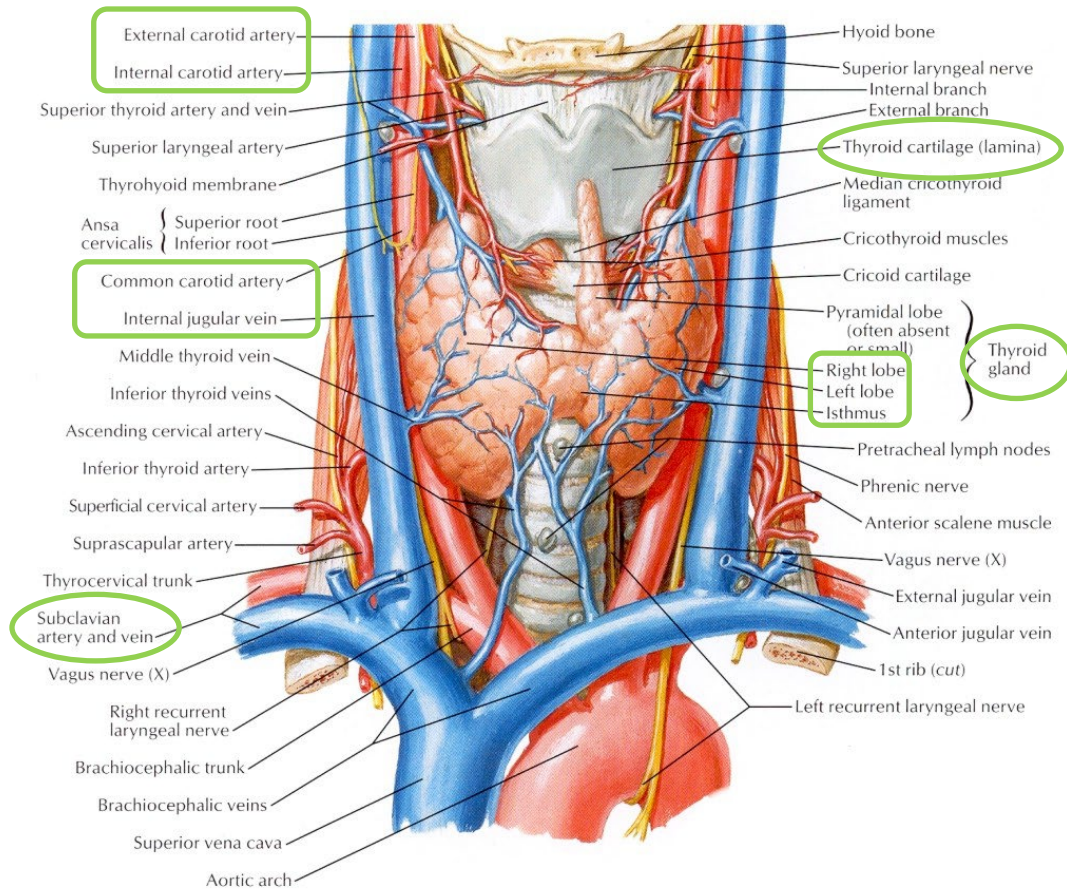
- Correlate anatomic structures identified during live-dissection with findings on ultrasound
- Demonstrate the ability to describe and identify normal ultrasound anatomy in the neck
- Describe the difference in appearance between veins and arteries
- Select the appropriate transducer and optimizing image capture by adjusting function keys

HANDS-ON OBJECTIVES

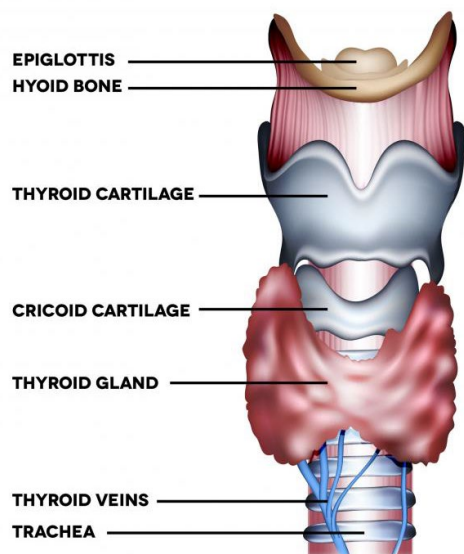
- Identify Structures in the Neck
 - Thyroid cartilage
 - Thyroid gland (isthmus, right and left lobes)
 - Trachea and Tracheal rings
 - Esophagus
 - Common carotid artery
 - Internal jugular vein
 - Sternocleidomastoid muscle
 - Carotid bulb
 - Internal carotid artery
 - External carotid artery
 - Subclavian artery

○ NECK ULTRASOUND

Gross Anatomy



Credit: SHB Neck lecture, Slide 56



wiseGEEK

Ultrasound Anatomy

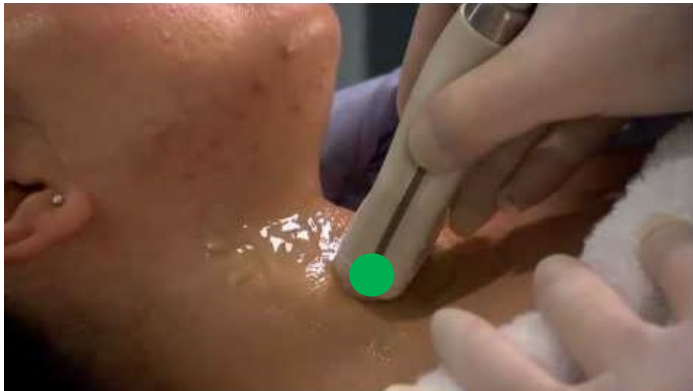Neck Ultrasound Scanning Protocol: <https://www.youtube.com/watch?v=zozD2x2Ll4Q>

Probe Selection:

- Linear

Patient Positioning and Preparation:

- Supine for scan of anterior neck
- Patient's head turned to the contralateral (opposite) side to evaluate the lateral neck structures



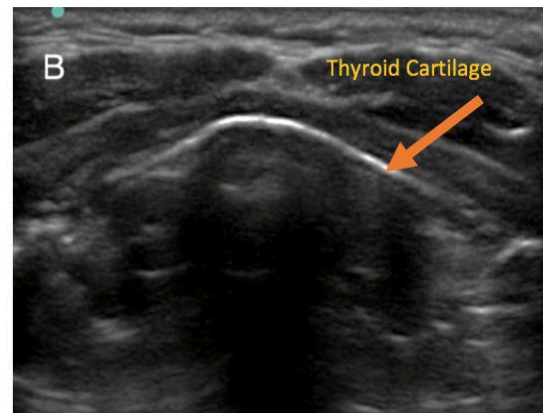
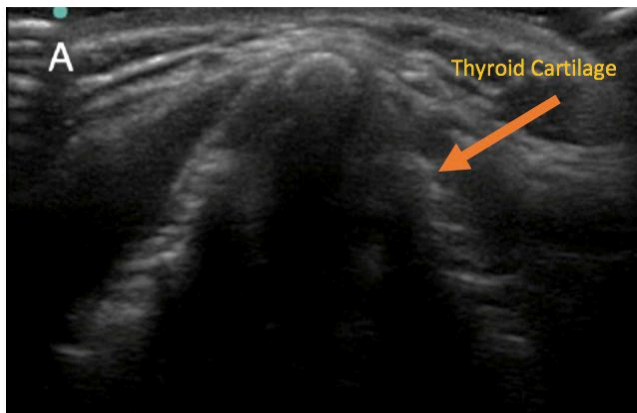
Credit: <https://www.youtube.com/watch?v=iIO09kGSRkl>

1. Technique:

- Transverse (axial) plane
- Place linear probe midline and survey the neck superiorly and inferiorly. Note the thyroid cartilage and its triangular shape.
- Take note of how the shape of the thyroid cartilage changes as you sweep the probe along the anterior aspect of the neck.

Structure to Identify:

- **Thyroid cartilage**

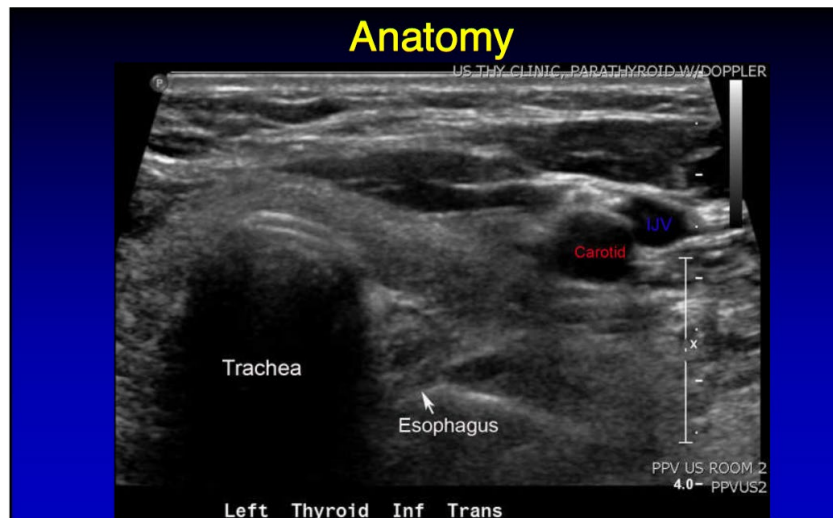


2. Technique:

- Transverse (axial) plane
- Sweep the probe inferiorly (caudally) to see the tracheal rings, the isthmus and the right and left lobes of the thyroid gland.
- Note the relationship and difference of appearance between the thyroid gland and the trachea.
- A collapsed esophagus will lay to the left and inferior to the trachea. To better visualize the esophagus, scan as your patient takes a drink. You should see the lumen of the esophagus distend as the anechoic fluid moves through the esophagus.

Structures to Identify:

- Thyroid gland (Isthmus, Lobes)
- Trachea and tracheal rings
- Esophagus

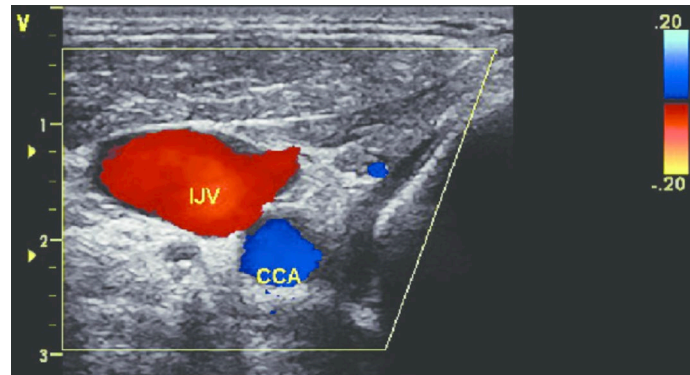


3. Technique:

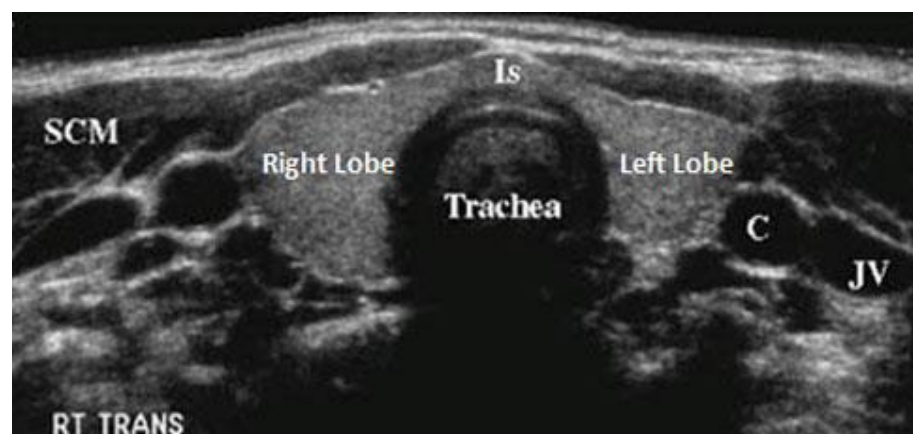
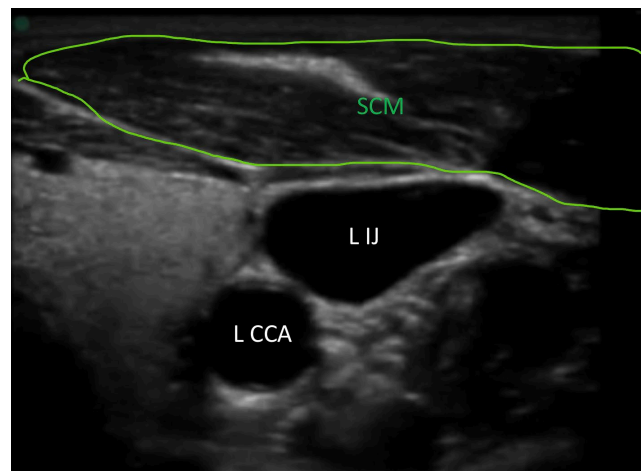
Part 1:

- Slide the probe slightly to the patient's right, off midline to interrogate the right lobe of the thyroid. The probe will remain in transverse orientation.
- The carotid artery is just lateral to the thyroid gland, and the internal jugular (IJ) vein is usually anterolateral to the carotid artery. Be cautious not to apply too much pressure on the vessels as the IJ may not be visible due to being fully compressed.
- Further differentiate the carotid artery from the IJ by noticing the compressibility and ovoid shape of the IJ and the pulsatility of the carotid artery. Sometimes the IJ may appear to pulse, however, the pulsation is originating from the carotid artery underneath it.
- Have the patient valsalva (attempted exhalation against a closed airway or "bearing down, like having a bowel movement") in order to distend the IJ.
- Changing the exam type to "Color Doppler" and placing the box over the vessels will reveal flow identified as either red, blue, or a combination. As blood flow in color Doppler is relative to the probe, the probe must be fanned to point cephalad or caudally to accurately determine the direction of flow.

- Remember the acronym BART: “Blue Away, Red Towards.” If the blood flow is moving away from the transducer, it will appear blue, and red if the flow is moving towards the transducer. The color within the vessel will change depending on how the probe is oriented.



- Anterior to the vessels you will find the sternocleidomastoid muscle. Muscle will have a striated appearance.



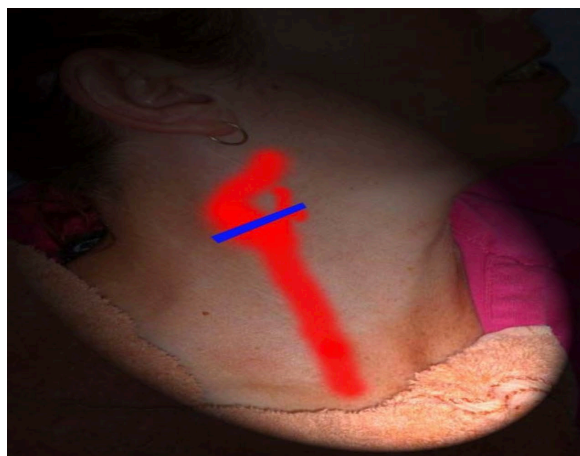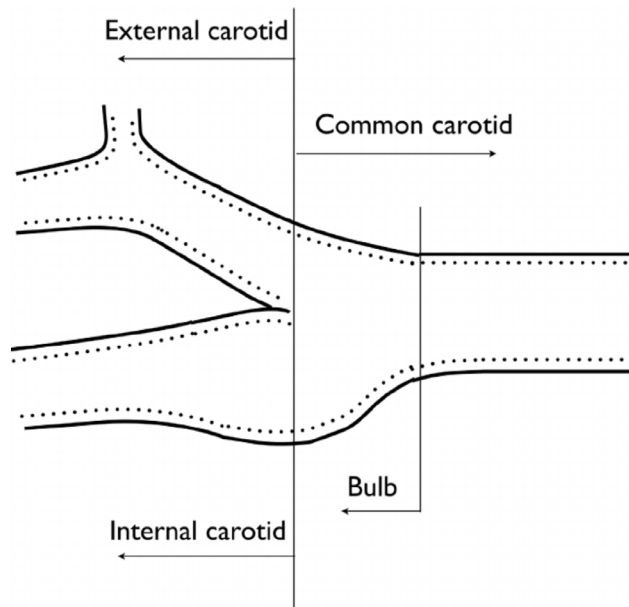
(Is – isthmus of thyroid lobe; SCM = sternocleidomastoid muscle; C – carotid artery; JV – internal jugular vein)
Credit: <http://www.chop.edu>

Structures to Identify:

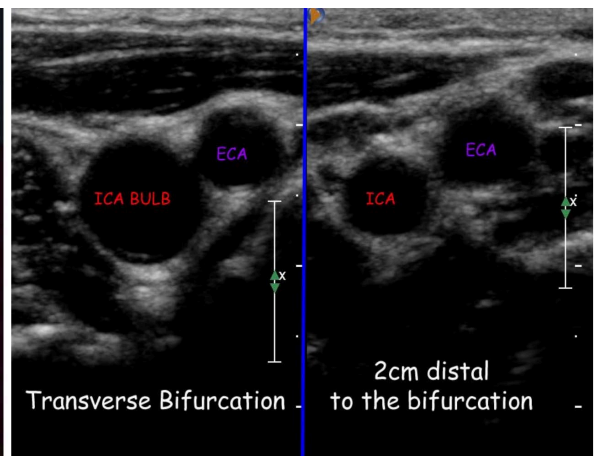
- Common carotid artery
- Internal jugular vein
- Sternocleidomastoid muscle

Part 2:

- Sweep the probe cranially along the right common carotid artery (CCA) to identify the carotid bulb, which is where the carotid artery widens. The common carotid artery will branch near the angle of the mandible into the internal carotid artery (ICA) and external carotid artery (ECA). The ICA is located posterior and lateral to the ECA.

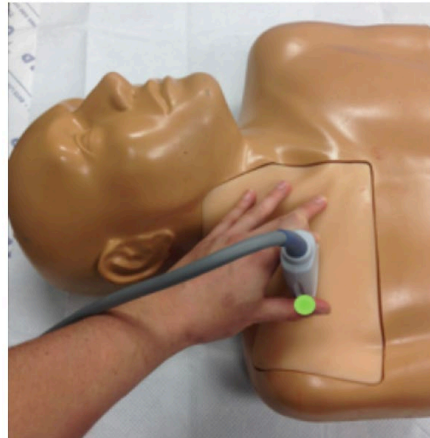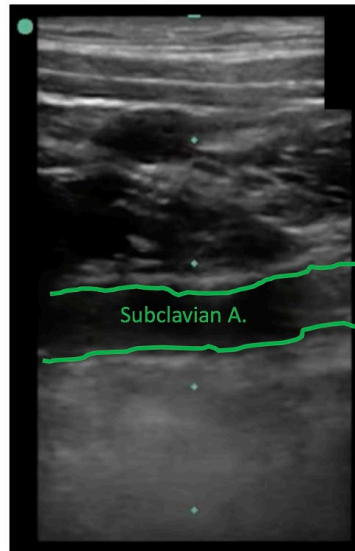


Transverse bifurcation scan plane.



These transverse images show the difference in ICA-bulb vs ECA at the bifurcation and then approximately 1cm further distal.

- Sweep the probe caudally along the right common carotid artery to identify the subclavian artery at the level of the clavicle. As the subclavian artery runs medial to lateral, the vessel will appear in long axis (running horizontally along the screen).



Structures to Identify:

- Carotid bulb
- Internal carotid artery
- External carotid artery
- Subclavian artery